

Ectopic synthesis of vitellogenin in testis and epididymis of estrogen-treated lizard *Podarcis sicula*



Mariailaria Verderame*, Ermelinda Limatola, Rosaria Scudiero

Department of Biology, University Federico II, Via Mezzocannone 8, 80134 Napoli, Italy

ARTICLE INFO

Article history:

Received 4 March 2016

Revised 6 June 2016

Accepted 8 June 2016

Available online 09 June 2016

Keywords:

Epididymis

Estrogen

Podarcis sicula

Reptiles

Testis

Vitellogenin extrahepatic expression

ABSTRACT

In oviparous vertebrates, vitellogenin (VTG) is the major yolk precursor synthesized in the liver of sexually mature females during the reproductive period. In males, the VTG gene is silent, but it may be activated by estradiol-17 β (E2) or estrogen-like substances. Until now, extra-hepatic expression and synthesis of VTG after estrogen exposure has been reported only for aquatic vertebrates. This study demonstrates the ability of testis and epididymis of the terrestrial oviparous lacertid *Podarcis sicula* to synthesize VTG following E2 exposure. The results of *in situ* hybridization and immunohistochemistry analysis show the presence of both VTG mRNA and protein in these districts besides the known induction in the liver. The possible contemporaneous uptake of the E2-induced hepatic VTG by means of the specific vitellogenin receptor has been also evaluated. Finally, histological analysis shows that the E2-treatment during the mating season impairs spermatogenesis.

© 2016 Published by Elsevier Inc.

1. Introduction

In the last years, the role of estrogen in the males has been largely re-evaluated. The righteous physiological levels of this typically female hormone allow the progression of spermatogenesis and regulate the function of the epididymis in males (Carreau and Hess, 2010; Joseph et al., 2010). Many Endocrine Disruptor Chemicals (EDC) with estrogen-like action interfere with the male reproductive physiology causing skewed sex ratio, diminished sexual behaviour, decreased sperm count, reduced spawning and fertilization (Hayes et al., 2011; Huang et al., 2015). Further, in male liver the unwanted estrogenic exposure induces vitellogenin synthesis with the consequence of its presence at detectable level in the plasma (Sumpter and Jobling, 1995). The VTG gene is silent but it may be activated by estradiol-17 β (E2) or estrogen-like substances (Ruggeri et al., 2008; Verderame and Limatola, 2010; El-Sayed Ali et al., 2014; Staniszewska et al., 2014).

In many estrogen-treated male fishes has been reported the extrahepatic expression of VTG in several ectopic sites as heart, brain, epidermis, gills, in adipose tissue, intestines and muscles and in the gonad (Yin et al., 2009; Jin et al., 2008; Islinger et al., 2003; Tingaud-Sequeira et al., 2012; Wang et al., 2005; Wang et al., 2010). In zebrafish males, the 17 α -ethinylestradiol induces VTG expression and synthesis in dose- and time-dependent pat-

tern in liver, skin and eye (Zhong et al., 2014). The germ cells of medaka males, treated with E2 or estrogen-like substances, are able to incorporate and accumulate VTG (Kobayashi et al., 2005). The presence of VTG mRNA and protein was also detected in the testis of the cartilaginous fish *Torpedo marmorata* experimentally treated with E2 (Del Giudice et al., 2011). In the rainbowfish *Melanotaenia fluviatilis* exposed to E2 VTG mRNA was detected in the testes (Shanthanagouda et al., 2013) and VTG protein was localized in the cellular spaces surrounding the spermatids and in association with connective tissue of the sperm tubules (Woods et al., 2009). RT-PCR analysis in the testes of *Tanichthys albonube* exposed to estrogen showed the presence of VTG-mRNA (Wang et al., 2010).

Usually, in these organisms estrogen showed severe adverse effects such as disruption of reproductive cycle, abnormal morphology and testicular growth inhibition, change of sex ratio and sex reversal (Gray and Metcalfe, 1997; Gronen et al., 1999; Scholz and Gutzeit, 2000; Metcalfe et al., 2001; Andersen et al., 2003; Kavanagh et al., 2004).

In this context little or nothing is known in terrestrial vertebrates. Among these, our model is the oviparous lizard *Podarcis sicula* of which are known the reproductive cycle in females and males (Filosa, 1973). In this species we recorded VTG synthesis in wildlife females (Carnevali et al., 1991) and in liver and plasma of males experimentally treated with E2 (Verderame and Limatola, 2010) or exposed to estrogen-like contaminated food or soil (Verderame et al., 2011, 2016).

* Corresponding author.

E-mail address: ilaria.verderame@unina.it (M. Verderame).

The aim of the present research was to determine in this lizard if the male gonad may be a site of ectopic synthesis and/or accumulation of VTG. The presence of VTG mRNA and protein in the testis and epididymis of sexually mature males experimentally treated with E2 was analyzed by *in situ* hybridization and immunohistochemistry; the morphology of seminiferous tubules and epididymis was also evaluated. Furthermore, to assess if the testis and epididymis are able to accumulate the circulating E2-induced VTG of hepatic origin, we cloned and sequenced a fragment of *P. sicula* vitellogenin receptor (VTGR) used as probe for *in situ* hybridization analysis.

2. Materials and methods

2.1. Animals and experimental treatment

Adult males of lizard *Podarcis sicula* of field origin (about 7.5–8 cm snout-vent) were caught in the outskirts of Naples (Italy) during the mating period (March–May) ($n = 44$), kept in terrariums at natural temperature and photoperiod and fed *ad libitum* with larvae of *Tenebrio molitor*.

For the estrogen treatment, animals received an intraperitoneal injection of E2 (168 ng/100 μ l, i.e. 20 ng/g body weight) in reptile physiological solution (NaCl 0.07%) every second day. Control animals were injected with the physiological saline solution. Groups of ten animals were sacrificed after 2 and 8 weeks of treatment. These E2 doses and times of treatments elicit the recovery of VTG protein in male serum (Verderame and Limatola, 2010). Four animals were sacrificed immediately after the capture (t0 control animals).

All the animals were killed by decapitation after deep anaesthesia with ketamine hydrochloride (Parke-Davis, Berlin, Germany), 325 μ g/g body weight; testes, epididymides and liver were quickly removed and immediately processed for the histological analyses.

The experiments were approved and carried out in compliance with the ethical provisions enforced by the National Committee of the Italian Ministry of Health on *in vivo* experimentation (Department for Veterinary Public Health, Nutrition and Food Safety, SCN/2D/2000/9213), and organized to minimize animals number and suffering.

2.2. Cloning of lizard vitellogenin receptor (VTGR) cDNA fragment

Total RNA from ovaries of *P. sicula* breeding females was used for cloning a VTGR cDNA fragment as probe for the subsequent *in situ* hybridization analysis. Ovaries were homogenized in the Tri-Reagent solution (Sigma Aldrich) and the total RNA was purified according to the manufacturer's protocol. The concentration and purity of the obtained total RNA dissolved in diethylpyrocarbonate (DEPC)-treated water were determined by UV absorbance spectrophotometry; RNA integrity was checked using 1% agarose gel electrophoresis. An aliquot (5 μ g) of this RNA was reverse-transcribed by using the AffinityScript kit (Agilent Technologies); the reaction was performed using a mixture of 25 pmol random primers, according to the manufacturer's protocol. The resulting first-strand cDNA was amplified by PCR using forward (5'-ATGACTG CAGTGATGGTAGTGA-3') and reverse (5'-CTTGCACTGTCATCTC CAT-3') specific primers for VTGR. The primers were designed on a fragment of the nucleotide sequence of chicken VLDL/VTGR available at the EMBL Nucleotide Database (NM205229.1). The PCR reaction mixture contained 0.5 μ M of each primer, 1.5 unit of Taq DNA Polymerase (Euroclone), 1 \times PCR buffer, 0.2 mM of each dNTP and 1.5 mM MgCl₂. The PCR thermal setting was as follows: 4 min at 94 °C; 38 cycles of 30 s at 94 °C, 40 s at 50 °C, 1 min at 72 °C; 7 min at 72 °C. The PCR products were separated in 1.2% agarose gel and visualized by ethidium bromide staining. The amplified

fragment was eluted by using the agarose gel extraction kit (5 PRIME) according to the manufacturer's protocol, and directly sequenced by Primm Biotech. The identity of the cDNA fragment was evaluated by matching the sequence to the nucleotide/protein sequences available at the EMBL Database. The *P. sicula* VTGR mRNA fragment obtained by PCR is available in the EMBL Nucleotide Database under the accession number LN874043.1

2.3. Histology

Testes with attached epididymis and liver were fixed in Bouin's fluid (Mazzi, 1977), and processed for paraffin wax embedding according to routine protocols. Sections of 7 μ m in thickness were obtained with Reichert-Jung 2030 microtome. Sections were stained with Mallory's trichrome modified by Galgano (Mazzi, 1977) to show general morphology or used for *in situ* hybridization (ISH) and immunocytochemistry (ICC) analysis. For both ICC and ISH analyses, were processed ten slides, each one with four attached sections. All the histological results were examined by using a Nikon-MicroPhot-FXA light microscope.

2.4. *In situ* hybridization

ISH was performed on adjacent sections with VTG or VTGR cDNA probes, as previously described (Verderame et al., 2011, 2012a; Verderame, 2014). Briefly, dewaxed sections were treated with proteinase K (10 lg/ml) at 50 °C for 10 min. Digoxigenin (DIG)-labeled probes were used at a concentration of 80 ng/100 μ l in hybridization buffer (Tris-HCl 0.02 M, pH 7.5; NaCl 0.3 M; EDTA 0.01 M; DTT 0.1 M; Formamide 50%; Denhardt's 1 \times ; tRNA 100 μ g/ml; ss-DNA 100 μ g/ml) overnight at 50 °C in a moist chamber. The slides were incubated with RNase mix at 37 °C for 30 min and in the same mix without RNase at 37 °C for 30 min, washed in 2 \times SSC for 3 min, in 0.1 \times SSC at 60 °C 15 min, and in NTP (Tris-HCl 0.1 M, pH 7.5; NaCl 0.15 M) and then incubated in 2% blocking solution (Roche Diagnostics, Mannheim, Germany) in maleic acid buffer (0.1 M maleic acid; 0.15 M NaCl, pH 7.5) for 1 h. The sections were kept overnight at 4 °C with an alkaline phosphatase-conjugated sheep anti-DIG antibody (Roche Diagnostics) (1:2500) in blocking solution and rinsed in NTP buffer for 30 min and in NTM buffer (Tris-HCl 100 mM, pH 9.5; MgCl 50 mM; NaCl 100 mM) for 30 min. Finally, the sections were kept in the color detection substrate solution BCIP/NBT (nitro-blue tetrazolium and 5-bromo-4-chloro-3-indolyphosphate) in the dark at room temperature as recommended by the manufacturer (Roche) in NTM until appearance of the color. For negative control, the hybridization solution did not contain cDNA probes.

2.5. Immunohistochemistry

For VTG localization, testis epididymis and liver sections were incubated with an homologous primary anti-VTG antibody (1:1000) (Rosanova et al., 2002) in phosphate buffer (PB) 0.1 M pH 7.4 overnight at 4 °C, washed in the same buffer and incubated with secondary polyclonal biotinylated anti-rabbit antibody (Pierce, Rockford, USA) (1:500 in PB). To detect antigen, we used the ultrasensitive ABC staining reagent kit (Pierce, USA) and diaminobenzidine (DAB 1 mg/ml; Sigma). Negative control sections were obtained by omitting incubation with primary antibody.

3. Results

All the untreated animals killed at time 0 or injected with physiological solution showed the same features. Hence, from now they will be indicated as control males.

3.1. Testis histology

Testes of control males stained with Mallory's trichrome showed the seminiferous epithelium filled with all germ cells from spermatogonia to spermatozoa, as expected in the mating period (Fig. 1a). After 2 weeks of E2-treatment, the lumen of the tubules was wide and several empty spaces were evident among germ cells (Fig. 1b). The seminiferous epithelium was reduced in thickness and consisted of spermatogonia, primary spermatocytes, very few secondary spermatocytes, elongated spermatids and spermatozoa

(Fig. 1b). In the testis of 8 weeks E2-treated animals, was evident an abundant connective tissue surrounding the seminiferous tubules (Fig. 1c). In the most damaged tubules oocyte-like structures were detectable among the germ cells (Fig. 1c).

3.2. VTG-mRNA and protein localization in testis and liver

ISH analysis showed, in E2-treated males, a strong positivity in all germ cells of the seminiferous epithelium (Fig. 2a), regardless of the length of the treatment. In wildlife untreated males no

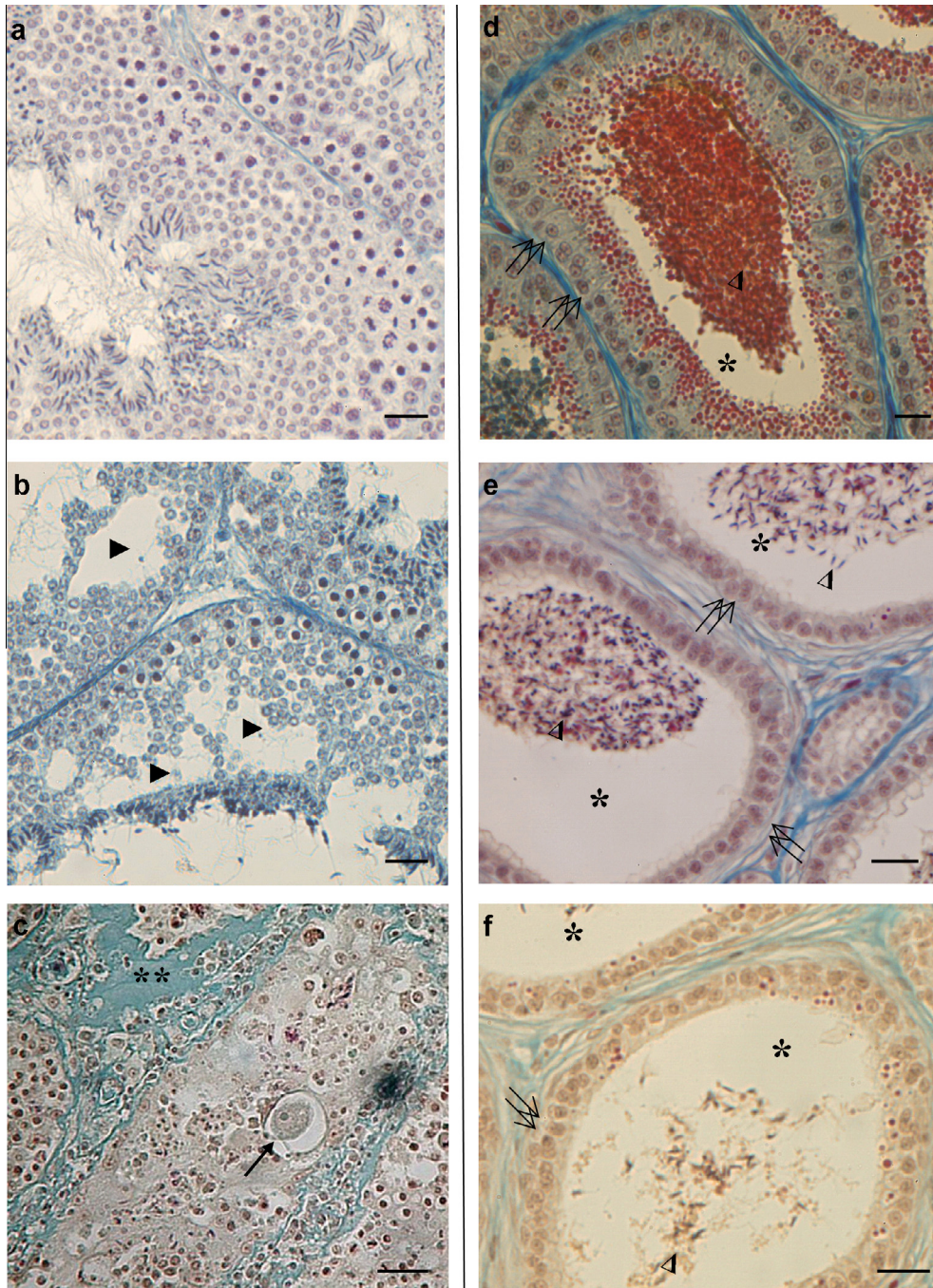


Fig. 1. Histology of testis (a, b, c) and epididymis (d, e, f) during the mating period. (a) Testis of control males: all stages of spermatogenesis are evident in the seminiferous epithelium. (b) Testis of E2-treated samples for 2 weeks: in the seminiferous epithelium several empty spaces (▶) are evident. (c) Testis of E2-treated samples for 8 weeks: abundant connective tissue (**) and an oocyte-like structure evident in the tubule (↑). (d) Epididymis of control males: the epithelium lining the corpus is cylindrical with elongated cells (↑↑) secreting a lot of granules (*) that mask the sperm in the lumen (Δ). (e) Epididymis of E2-treated samples for 2 weeks: the epithelium of the corpus (↑↑) is regressed with few granules mixed with few sperms in the lumen (*) (Δ). (f) Epididymis of E2-treated samples for 8 weeks: the epithelium of the corpus (↑↑) is regressed even if some residual granules, representative of the breeding season, are still present in the cells. The granules are almost absent in the lumen where rare sperms are evident (Δ). The bar is 30 μm.

VTG-mRNA was detected in the seminiferous epithelium (Fig. 2b). No reaction was present on sections incubated by omitting VTG cDNA probe (data not shown).

ICC analysis, performed using the homologous anti-VTG antibody, demonstrated the presence of immunoreactive VTG (irVTG) in all the few germ cells present in testis of the E2-treated lizards (Fig. 2c). In wildlife untreated animals, no irVTG was evident in germ cells (Fig. 2d). No immunoreactivity was observed in E2-treated sections incubated by omitting primary antibody (data not shown).

The reaction conducted to verify the presence of VTG, mRNA or protein in the liver of E2 treated males, were always positive as expected (Fig. 2e, f). No reaction was observed in the control

sections incubated by omitting VTG cDNA probe or primary antibody (data not shown).

3.3. Epididymis histology

The *P. sicula* epididymal duct is partitioned into *efferent ductules*, *corpus* and *cauda*. During the mating period, in control lizards the epididymal *corpus* showed the typical morphology, already described (Verderame et al., 2012a), with elongated lining cells, engaged in a massive secretory activity and a lot of spermatozoa and secretory granules in the lumen (Fig. 1d). After 2 weeks, in E2-treated specimens, the epididymal *corpus* showed a non-secreting epithelium and few sperms inside the lumen (Fig. 1e);

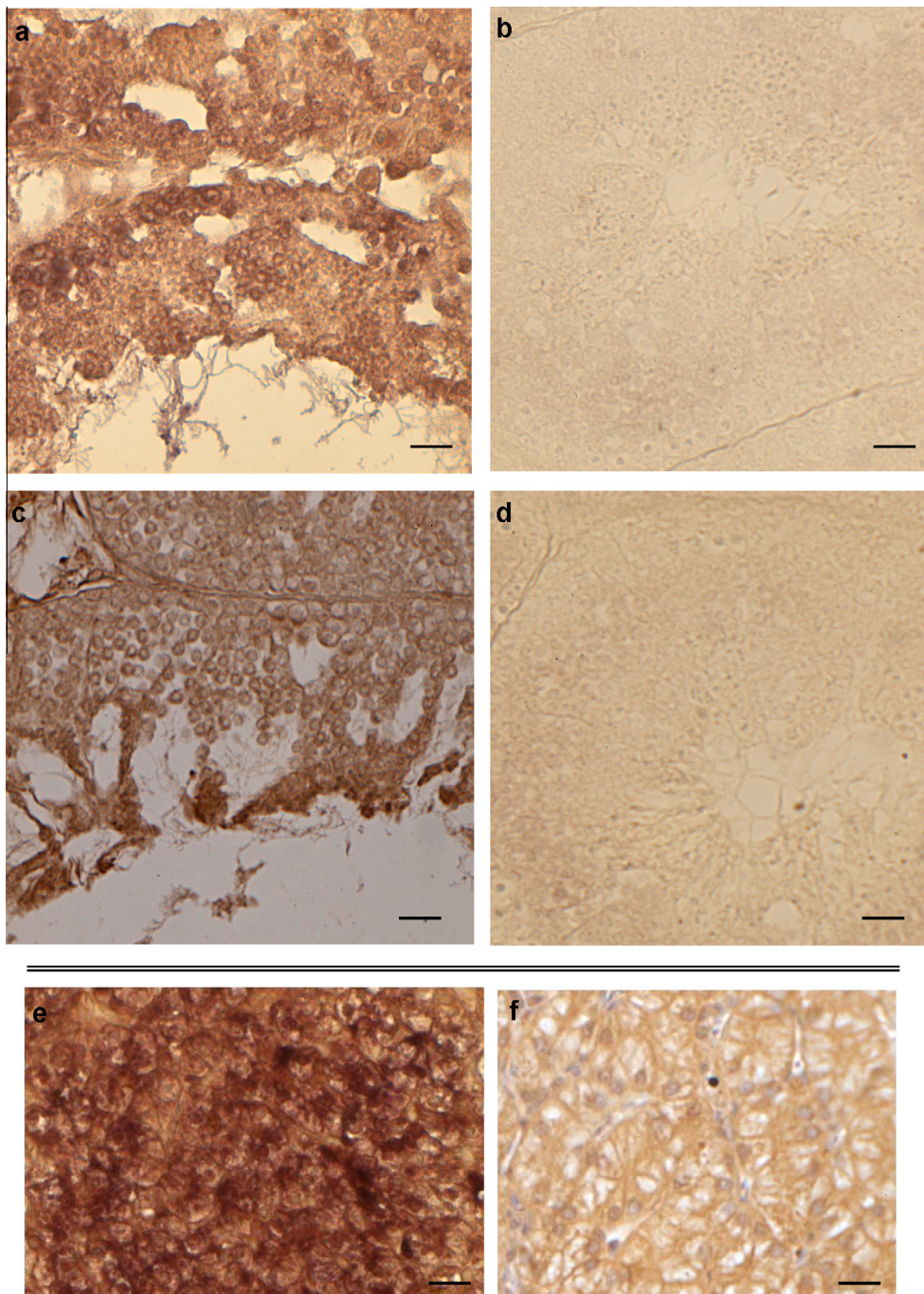


Fig. 2. VTG localization in the testis and liver. E2-treated males in the reproductive period (a, c, e, f): VTG-mRNA evidenced by ISH (a, e) and VTG protein by ICC (b, f) in the seminiferous epithelium. Control males: no VTG-mRNA (c) or VTG protein (d) is present in the germ cells from the basis of the epithelium up to the lumen. The bar is 30 μ m.

after 8 weeks of treatment, rare sperms are present in the lumen, and the *corpus* showed the typical structure of the natural post-mating refractory period (Fig. 1f).

3.4. VTG-mRNA and protein localization in epididymis

ISH analysis, performed on E2-treated animals showed a strong positivity to VTG probe in the *efferent ductules*, *corpus* and *cauda* (Fig. 3a), regardless of the length of the treatment. No VTG transcripts were detected in epididymis of wildlife untreated samples (Fig. 3b). Sections incubated by omitting VTG probe were always negative (data not shown). irVTG was detected in *efferent ductules*, *corpus* and *cauda* of all the E2-treated lizards (Fig. 3c). In wildlife animals, irVTG was absent in the epididymis compartments (Fig. 3d). The VTG protein was undetectable on sections incubated omitting primary antibody (data not shown).

3.5. Localization of VTGR transcripts in testis and epididymis

To evaluate the localization of VTGR transcripts in testis and epididymis of E2-treated lizards, a VTGR cDNA fragment was cloned and sequenced by RT-PCR analysis performed on total RNA from ovaries of sexually mature lizards. Specific primers (see Methods section) were designed on the homologous sequence of *Gallus gallus*. PCR reactions gave rise to a 208 bp DNA fragment encoding a polypeptide of 69 amino acids, sharing 86,9% identity with the corresponding region of chicken VTGR.

In E2-treated animals, ISH analysis performed with the DIG-labeled VTGR homologous probe showed the absence of transcripts both in the seminiferous epithelium and in the whole epididymis (Fig. 4a, c). As expected, no positivity was detected in

testis and epididymis of control lizards (Fig. 4b, d). Sections of lizard ovary used as controls to test the dig-labeled VTGR probe were positive to the reaction (Fig. 4e).

4. Discussion

Data herein described highlight for the first time that E2 is able to induce the extrahepatic expression and synthesis of VTG in testis and epididymis of the terrestrial oviparous vertebrate *Podarcis sicula* and affects the progression of spermatogenesis.

In *P. sicula* females during the breeding season (March–July) each ovulatory waves is characterized by a peak of both E2 and VTG. In non-breeding season (August–February), VTG is absent both in plasma and ovary and the levels of endogenous E2 are low (Carnevali et al., 1991; Verderame et al., 2012b). In males, the VTG is always absent, despite the highest level of circulating E2 is detectable during the post-mating refractory period (Angelini and Botte, 1992). However, in these animals the experimental administration of estrogens is able to induce the expression of the silent VTG gene in the liver, as observed in all the oviparous vertebrates so far investigated (Cedrà et al., 1996; Kobayashi et al., 2005; Verderame and Limatola, 2010).

The presence of VTG-mRNA and protein in the seminiferous epithelium and in epididymis proves that in male lizards estrogenic exposure elicits VTG expression and synthesis in extrahepatic tissues. In lizard testis, VTG transcripts and/or protein are localized in germ cells regardless of the stage of differentiation, differently from what observed in *Torpedo marmorata* where the E2-induced expression of VTG in male testis depends on the cellular stage (Del Giudice et al., 2011).

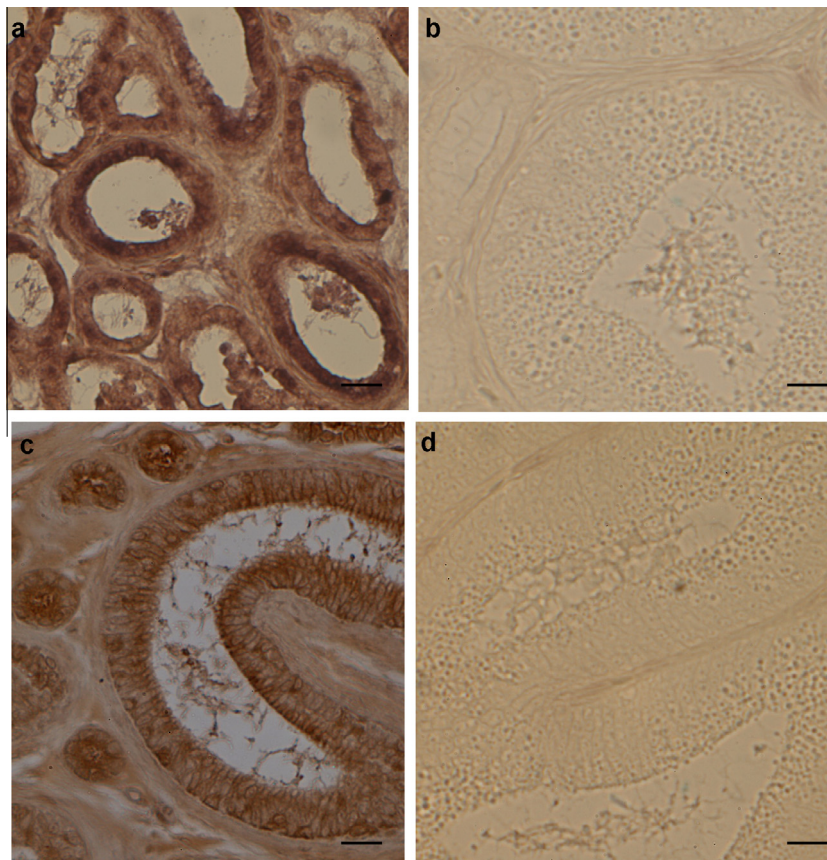


Fig. 3. VTG localization in the epididymis. E2-treated males (a, c): VTG-mRNA and VTG protein (c) are present in the reduced epithelium of the epididymal ducts. Control males (b, d): no VTG-mRNA (d) neither protein (e) is present. The bar is 30 µm.

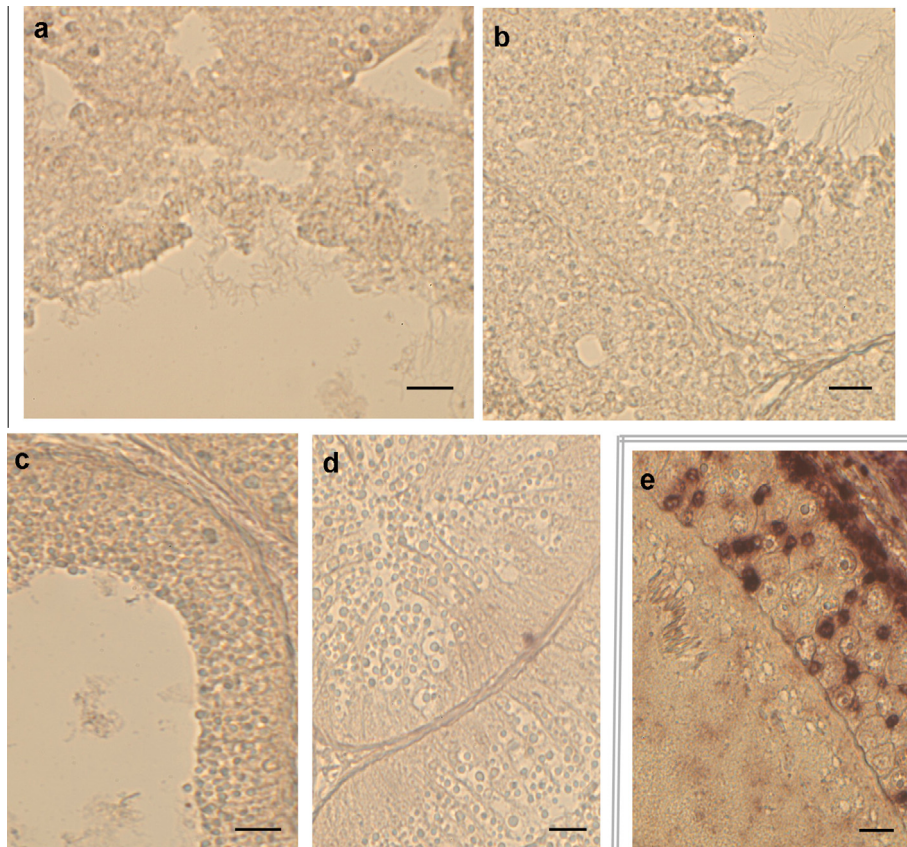


Fig. 4. VTGR-mRNA localization in the testis (a, b) and epididymis (c, d). None hybridization signal for VTGR-mRNA is evident in the testis and epididymis of both E2-treated (a, c) and control males (b, d). VTGR-mRNA signal is present in lizard ovary of the breeding period (e). The bar is 30 μm .

The present results demonstrate that the E2-treatment also induces VTG-mRNA and protein along the altered epididymal duct. Our previously results demonstrated that the epididymis of *Podarcis* is an estrogen-responsive tissue and the typical secretory activity, occurring during the mating period in the *corpus*, can be switched off by the E2-induced expression of the estrogen receptor- α (ER α). Possibly, the presence of VTG in altered epididymal ducts might be a consequence of an increased expression of ER α in the same district (Verderame et al., 2012a). On the other hand the biosynthesis of VTG in the liver of wildlife females or of the E2-treated males estrogen-treated males is positively related with the production of VTG (Verderame and Limatola, 2010).

The immunoreactive VTG found in lizard testis and epididymis could have a dual origin. It is conceivable that VTG protein could be synthesized from the transcripts present in the same cells but it could not be excluded that, as occurs in the ovary during the oocyte vitellogenesis (Limatola and Filosa, 1989), the hepatic VTG protein, synthesized under estrogenic stimulation and released into the bloodstream, could also be taken up by receptor mediated endocytosis also in the testis. The failure to detect VTGR transcripts in testis and epididymis of E2-treated lizards may suggest that the testicular VTG detected in these animals may derives entirely from the biosynthetic process locally activated by E2.

In *P. sicula*, during the mating period an intense spermatogenic activity take place in the testis and a large amount of germ cells is present in the seminiferous epithelium (Verderame et al., 2014). The presence of VTG in male reproductive tissues is index of injury. In fact, following injections of 17 β -estradiol, the histological examination revealed severe effects on the testicular structure. In particular, in the experimental group injected with E2 for two weeks, the enlargement of the lumen of the seminiferous tubules, the reduction in thickness of the epithelium and the presence of

some empty space among the germ cells indicate a general slow-down of spermatogenesis with a failure in the replacement of cells from the basal compartment of the seminiferous tubules. Impairment of spermatogenesis and alterations in testicular and epididymal structures have also been observed in *Podarcis* males feeded with larvae polluted by nonylphenol (Verderame and Limatola, 2015). Many aquatic vertebrates injected with estrogens or exposed to environmental estrogenic contaminants show the impairment of spermatogenesis and the arrest of reproductive cycle (Christiansen et al., 1998; Kinnberg et al., 2000; Bjerregaard et al., 2006).

Present data also demonstrate that the major damages in the seminiferous tubules are correlated with the length of the E2 treatment. In particular, the presence of an abundant connective tissue surrounding the tubules and the presence of rare germ cells are indicative of a total block of spermatogenesis in 8-weeks-E2-treated males. This treatment also led to the appearance of oocyte-like structures in the tubules. It is known in rats that estrogen stimulate connective tissue hyperplasia of some parts of the male reproductive tract (Howard and Allen, 1957). The presence of oocyte-like cells in male gonad is reported in some fishes experimentally or environmentally exposed to estrogenic compounds (Shibata and Hamaguchi, 1988; Gray and Metcalfe, 1997; Hashimoto et al., 2000; Viganò et al., 2006; Kang et al., 2002; Zha et al., 2007) and, more interestingly, in the testis of quail or chick embryos after E2 or NP exposure (Stoll et al., 1993; Razia et al., 2006). Up today, the presence of oocyte-like cells in *P. sicula* testis has been described following the treatment with GnRH antagonist (Ciarcia et al., 1983).

In conclusion, data herein described demonstrate that the administration of E2 in *Podarcis sicula* induces VTG synthesis in ectopic districts as testis and epididymis and causes the impairment of reproduction with slowdown/inhibition of spermatogenesis.

In addition, the presence in the testis of oocyte-like structure after the prolonged E2 exposure, could be possibly due to a shift in the differentiation of male germ cells or to the persistence of primordial germ cells in the fully differentiated testis.

References

- Andersen, L., Holbech, H., Gessbo, A., Norrgren, L., Petersen, G.I., 2003. Effects of exposure to 17 α -ethinylestradiol during early development on sexual differentiation and induction of vitellogenin in zebrafish (*Danio rerio*). *Comp. Biochem. Physiol. C: Toxicol. Pharmacol.* 134 (3), 365–374.
- Angelini, F., Botte, V., 1992. Spermatogenesis in reptiles, dynamic and regulatory aspect. In: Dallai, R. (Ed.), Sex origin and Evolution. Mucchi Selected Symposia and Monographs UZI, Modena, Italy, pp. 211–230.
- Bjerregaard, L.B., Madsen, A.H., Korsgaard, B., Bjerregaard, P., 2006. Gonad histology and vitellogenin concentrations in brown trout (*Salmo trutta*) from Danish streams impacted by sewage effluent. *Ecotoxicology* 15, 315–327.
- Carnevali, O., Mosconi, G., Angelini, F., Limatola, E., Ciarcia, G., Polzonetti-Magni, A., 1991. Plasma vitellogenin and 17 beta-estradiol levels during the annual reproductive cycle of *Podarcis sicula* Raf. *Gen. Comp. Endocrinol.* 84, 337–343.
- Carreau, S., Hess, R.A., 2010. Oestrogens and spermatogenesis. *Philos. Trans. R. Soc. Lond. B Biol. Sci.* 296 (365), 1517–1535.
- Cedrà, J., Bruce, B.G., LaFleur Jr., G.J., Limesand, S., 1996. Pattern of vitellogenin and follicle maturational competence during the ovarian follicular cycle of *Fundulus heteroclitus*. *Gen. Comp. Endocrinol.* 103, 24e35.
- Christiansen, T., Korsgaard, B., Jespersen, Å., 1998. Effects of nonylphenol and 17 β -oestradiol on vitellogenin synthesis, testicular structure and cytology in male eelpout *Zoarces viviparus*. *J. Exp. Biol.* 201, 179–192.
- Ciarcia, G., Angelini, F., Botte, V., 1983. Effects of a chronic treatment with the luteinizing hormone-releasing hormone agonist, busserlin, on the gonads of the lizard *Podarcis sicula* Raf. *Atti della Accademia Nazionale dei Lincei*, 425–429.
- Del Giudice, G., Prisco, M., Agnese, M., Verderame, M., Limatola, E., Andreuccetti, P., 2011. Expression of vitellogenin in the testis and kidney of the spotted ray *Torpedo marmorata* exposed to 17 β -estradiol. *Gen. Comp. Endocrinol.* 174, 318–325.
- El-Sayed Ali, T., Abdel-Aziz, S.H., El-Sayed, A.F., Zeid, S., 2014. Structural and functional effects of early exposure to 4-nonylphenol on gonadal development of Nile tilapia (*Oreochromis niloticus*): a-histological alterations in ovaries. *Fish Physiol. Biochem.* 40 (5), 1509–1519.
- Filosa, S., 1973. Biological and cytological aspects of the ovarian cycle in *Lacerta s. Sicula* Raf. *Monit. Zool. Ital.* 7, 151–165.
- Gray, M.A., Metcalfe, C.D., 1997. Induction of testis-ova in Japanese Medaka (*Oryzias latipes*) exposed to p-nonylphenol. *Environ. Toxicol. Chem.* 16, 1082–1086.
- Gronen, S., Denslow, N., Manning, S., Barnes, S., Barnes, D., Brouwer, M., 1999. Serum vitellogenin levels and reproductive impairment of male Japanese medaka (*Oryzias latipes*) exposed to 4-tert-octylphenol. *Environ. Health Perspect.* 107, 385–390.
- Hashimoto, S., Bessho, H., Hara, A., Nakamura, M., Iguchi, T., Fujita, K., 2000. Elevated serum vitellogenin levels and gonadal abnormalities in wild male flounder (*Pleuronectes yokohamae*) from Tokyo Bay. *Jpn. Mar. Environ. Res.* 49, 37–53.
- Hayes, T.B., Anderson, L.L., Beasley, V.R., De Solla, S.R., Iguchi, T., Ingraham, H., Kestemont, P., Kniwald, J., Kniwald, Z., Langlois, V.S., Luque, E.H., McCoy, K.A., Muñoz-De-Toro, M., Oka, T., Oliveira, C.A., Orton, F., Ruby, S., Suzawa, M., Tavera-Mendoza, L.E., Trudeau, V.L., Victor-Costa, B.A., Willingham, E., 2011. Demasculinization and feminization of male gonads by atrazine: consistent effects across vertebrate classes. *J. Steroid Biochem. Mol. Biol.* 127, 64–73.
- Howard, E., Allen, J.C., 1957. The retarding influences of adrenalectomy and age on estradiol-induced connective tissue hyperplasia in seminal vesicles. *Endocrinology* 60, 785–796.
- Huang, Y., Wang, X.L., Zhang, J.W., Wu, K.S., 2015. Impact of endocrine-disrupting chemicals on reproductive function in zebrafish (*Danio rerio*). *Reprod. Domest. Anim.* 50, 1–6.
- Jin, Y.X., Wang, W.Y., Sheng, G.D., Liu, W.P., Fu, Z.W., 2008. Hepatic and extrahepatic expression of estrogen-responsive genes in male adult zebrafish (*Danio rerio*) as biomarkers of short-term exposure to 17 β -estradiol. *Environ. Monit. Assess.* 146, 105–111.
- Joseph, A., Hess, R.A., Schaeffer, D.J., Ko, C., Hudgin-Spivey, S., Chambon, P., Shur, B. D., 2010. Absence of estrogen receptor alpha leads to physiological alterations in the mouse epididymis and consequent defects in sperm function. *Biol. Reprod.* 82, 948–957.
- Kang, I.J., Yokota, H., Oshima, Y., Tsuruda, Y., Oe, T., Imada, N., Tadokoro, H., Honjo, T., 2002. Effects of bisphenol A on the reproduction of Japanese medaka (*Oryzias latipes*). *Environ. Toxicol. Chem.* 21, 2394–2400.
- Kavanagh, D.J., Waghorn, G., Jenner, L., et al., 2004. Demographic and clinical correlates of comorbid substance use disorders in psychosis: multivariate analyses from an epidemiological sample. *Schizophr. Res.* 66, 115–124.
- Kinnberg, K., Korsgaard, B., Bjerregaard, P., 2000. Concentration-dependent effects of nonylphenol on testis structure in adult platyfish *Xiphophorus maculatus*. *Mar. Environ. Res.* 50, 169–173.
- Kobayashi, K., Tamotsu, S., Yasuda, K., Oishi, T., 2005. Vitellogenin-immunohistochemistry in the liver and the testis of the Medaka, *Oryzias latipes*, exposed to 17 β -estradiol and p-nonylphenol. *Zool. Sci.* 22, 453e461.
- Limatola, E., Filosa, S., 1989. Exogenous vitellogenesis and micropinocytosis in the lizard *Podarcis sicula* treated with follicle-stimulating hormone. *Gen. Comp. Endocrinol.* 75, 165–176.
- Mazzi, V., 1977. In: Mazzi, V. (Ed.), *Manuale di tecniche istologiche e istochimiche*, pp. 63–278, Padova (Italy).
- Metcalfe, C.D., Metcalfe, T.L., Kiparissis, Y., Koenig, B.G., Khan, C., Hughes, R.J., Croley, T.R., March, R.E., Potter, T., 2001. Estrogenic potency of chemicals detected in sewage treatment plant effluents as determined by in vivo assays with Japanese Medaka (*Oryzias latipes*). *Environ. Toxicol. Chem.* 20, 297–308.
- Razia, S., Maegawa, Y., Tamotsu, S., Oishi, T., 2006. Histological changes in immune and endocrine organs of quail embryos: exposure to estrogen and nonylphenol. *Ecotoxicol. Environ. Saf.* 65, 364–371.
- Rosanova, P., Romano, M., Marciano, R., Anteo, C., 2002. Vitellogenin precursors in the liver of oviparous lizard, *Podarcis sicula*. *Mol. Reprod. Dev.* 63, 349–354.
- Ruggeri, B., Ubaldi, M., Lourdasamy, A., Soverchia, L., Ciccocioppo, R., Hardiman, G., Baker, M.E., Palermo, F., Polzonetti-Magni, A.M., 2008. Variation of the genetic expression pattern after exposure to estradiol-17 β and 4-nonylphenol in male zebrafish (*Danio rerio*). *Gen. Comp. Endocrinol.* 158, 138–144.
- Scholz, S.H., Gutzeit, O., 2000. 17 α -ethinylestradiol affects reproduction, sexual differentiation and aromatase gene expression of the medaka (*Oryzias latipes*). *Aquat. Toxicol.* 50, 363–373.
- Shanthanagouda, A.H., Nugegoda, D., Hassell, K.L., Patil, J.G., 2013. Exposure to estrogenic chemicals induces ectopic expression of VTG in the testis of rainbowfish, *Melanotaenia fluviatilis*. *Bull. Environ. Contam. Toxicol.* 91, 438–443.
- Shibata, N., Hamaguchi, S., 1988. Evidence for the sexual bipotentiality of spermatogonia in the fish, *Oryzias latipes*. *J. Exp. Zool.* 245, 71–77.
- Staniszewska, M., Falkowska, L., Grabowska, P., Kwaśniak, J., Mudrak-Cegiołka, S., Reindl, A.R., Sokołowski, A., Szumiło, E., Zgrundo, A., 2014. Bisphenol A, 4-tert-octylphenol, and 4-nonylphenol in the Gulf of Gdańsk (Southern Baltic). *Arch. Environ. Contam. Toxicol.* 67, 335–347.
- Stoll, R., Ichas, F., Fauconau, N., Maraud, R., 1993. Action of estradiol and tamoxifen on the testis-inducing activity of the chick embryonic testis grafted to the female embryo. *Anat. Embryol.* 188, 587–592.
- Sumpter, J.P., Jobling, S., 1995. Vitellogenesis as a biomarker for estrogenic contamination of the aquatic environment. *Environ. Health Persp.* 103, 173e178.
- Tingaud-Sequeira, A., Knoll-Gellida, A., Andre, M., Babin, P.J., 2012. Vitellogenin expression in white adipose tissue in female teleost fish. *Biol. Reprod.* 86, 38.
- Verderame, M., Limatola, E., Scudiero, R., 2016. Estrogenic contamination by manure fertilizer in organic farming: a case study with the lizard *Podarcis sicula*. *Ecotoxicology* 25, 105–114.
- Verderame, M., Limatola, E., 2015. Interferences of an environmental pollutant with estrogen-like action in the male reproductive system of the terrestrial vertebrate *Podarcis sicula*. *Gen. Comp. Endocrinol.* 213, 9–15.
- Verderame, M., 2014. The involvement of the androgen receptor in the secretion of the epididymal corpus in the lizard *Podarcis sicula*. *Int. J. Zool.* 2014 457830.
- Verderame, M., Angelini, F., Limatola, E., 2014. Spermatogenic waves and expression of AR and ERs in germ cells of *Podarcis sicula*. *Int. J. Zool.* 2014 965617.
- Verderame, M., Angelini, F., Limatola, E., 2012a. Expression of the estrogen receptor alpha switches off the secretory activity in the epididymal channel of the lizard *Podarcis sicula*. *Mol. Reprod. Dev.* 79, 107–117.
- Verderame, M., Caferio, G., Limatola, E., 2012b. Vitellogenin, oestradiol 17 β -b and its receptors in the lizard *Podarcis sicula*: cross-talk between growing oocytes and liver. In: *Advances in Zoology Research*, vol. 2. NOVA Publisher, pp. 245–258.
- Verderame, M., Limatola, E., 2010. Molecular identification of estrogen receptors (ER α and ER β) and their differential expression during VTG synthesis in the liver of lizard *Podarcis sicula*. *Gen. Comp. Endocrinol.* 168, 231–238.
- Verderame, M., Prisco, M., Andreuccetti, P., Aniello, F., Limatola, E., 2011. Experimentally nonylphenol-polluted diet induces the expression of silent genes VTG and ER α in the liver of male lizard *Podarcis sicula*. *Environ. Pollut.* 159, 1101–1107.
- Viganò, L., Mandich, A., Benfenati, E., Bertolotti, S., Porazzi, E., Agradi, E., 2006. Investigating the estrogenic risk along the river Po and its intermediate section. *Arch. Environ. Contam. Toxicol.* 51, 641–651.
- Wang, R.L., Gao, Y., Zhang, L.H., Zhang, Y.K., Fang, Z.Q., He, J.G., Zhang, W.M., Ma, G. Z., 2010. Cloning, expression, and induction by 17 β -estradiol (E-2) of avitellogenin gene in the white cloud mountain minnow *Tanichthys albonubes*. *Fish Physiol. Biochem.* 36, 157–164.
- Wang, H., Tan, J.T., Emelyanov, A., Korzh, V., Gong, Z., 2005. Hepatic and extrahepatic expression of vitellogenin genes in the zebrafish, *Danio rerio*. *Gene* 356, 91–100.
- Woods, M., Kumar, A., Barton, M., Woods, A., Kookana, R., 2009. Localisation of estrogen responsive genes in the liver and testis of Murray rainbowfish *Melanotaenia fluviatilis* exposed to 17 β -estradiol. *Mol. Cell. Endocrinol.* 303, 57–66.
- Yin, N., Jin, X., He, J., Yin, Z., 2009. Effects of adrenergic agents on the expression of zebrafish (*Danio rerio*) vitellogenin A α 1. *Toxicol. Appl. Pharmacol.* 238, 20–26.
- Zha, J., Wang, Z., Wang, N., Ingersoll, C., 2007. Histological alternation and vitellogenin induction in adult rare minnow (*Gobiocypris rarus*) after exposure to ethinylestradiol and nonylphenol. *Chemosphere* 66, 488–495.
- Zhong, L., Yuan, L., Rao, Y., Li, Z., Zhang, X., Liao, T., Xu, Y., Dai, H., 2014. Distribution of vitellogenin in zebrafish (*Danio rerio*) tissues for biomarker analysis. *Aquat. Toxicol.* 149, 1–7.