

## Observations on FGF immunoreactivity in the regenerating tail blastema, and in the limb and tail scars of lizard suggest that FGFs are required for regeneration

Lorenzo Alibardi

Dipartimento di Biologia Evoluzionistica Sperimentale, University of Bologna, via Selmi 3, 40126 Bologna, Italy, e-mail: [lorenzo.alibardi@unibo.it](mailto:lorenzo.alibardi@unibo.it).

**ABSTRACT.** Tail regeneration in lizards depends on the stimulation of growth factors, including Fibroblast Growth Factors (FGFs). Light and ultrastructural immunolocalization of FGFs was compared between the regenerating tail blastema and the limb where no regeneration occurs. A likely epithelial-mesenchymal transition occurs following amputation in both tail and limb and FGFs are present in the wound epidermis of both organs at 7-14 days post-amputation, and at lower intensity in mesenchymal cells of the blastema. Immunoreactivity for FGFs disappears in the limb wound epidermis after 14 days post-amputation and in the epithelium covering tails induced to form scars, whereas it remains in the apical tail epithelium. These observations suggest that scarring in the limb or the induced scarring in the tail correlate with the disappearance of FGFs. Basic FGF is concentrated in the incomplete basement membrane between the epidermis and the tail blastema where the essential signaling process that allows the continuous growth of the regenerative blastema may occur. The study suggests that the successful regeneration of lizard tail is dependent on the presence of FGFs in the wound epidermis, which are probably released into the blastema.

**KEY WORDS.** regenerating tail; scarring limb; Fibroblast Growth Factors; immunolocalization; ultrastructure

### INTRODUCTION

Lizards can regenerate an amputated tail while they cannot regenerate an amputated limb (MARCUCCI, 1925, 1930; BARBER, 1944; BELLAIRS & BRYANT, 1985; ALIBARDI & TONI, 2005). Lizards represent a non-mammalian, amniote model for the analysis of tissue regeneration (ALIBARDI, 2010a, b) closer to mammalian models than the amphibian model (MESHER, 1996; GERAUDIE & FERRETTI, 1998; STOCUM, 2006; CARLSON, 2007; HARTY et al., 2003). These reptiles allow analysis of the factors that limit tissue regeneration, and the results can be compared with the formation of scar tissue in warm-blooded amniotes such as mammals (ALIBARDI, 2010a,b).

Microscopical studies on tail regeneration have shown that a regenerative blastema and a large mass consisting of cartilaginous, fat, muscle and nervous tissues are formed (HUGHES & NEW, 1959; SIMPSON, 1965; COX, 1969; BELLAIRS &

BRYANT, 1985; ALIBARDI & SALA, 1988). The blastema is the loose connective tissues formed above the stump from the accumulation of a mass of proliferating mesenchymal-like cells, which are covered by a regenerating or wound epidermis. The growth and progressive differentiation of cells within the blastema gives rise to the new tail. Conversely, in the limb, after an intense and lasting inflammatory response, no blastema is formed and the connective tissue forms scar tissue as it does in mammalian wounds (BARBER, 1944; ZICKA, 1969; ALIBARDI, 2010a,b).

In the tail the nervous tissues, especially the spinal cord and the central ependyma, are essential components of the regeneration process and directly or indirectly stimulate the regeneration of the other tissues (SIMPSON, 1970; WHIMSTER, 1978; ALIBARDI, 2010b). Also, the presence of an apical wound epidermis with an incomplete basement membrane, separating epidermal cells from the underlying mesenchymal cells

of the blastema, is essential for the continuous regeneration of the tail (ALIBARDI, 1994a, b, 2010a, b). It is, however, unknown whether in this region an exchange of trophic material between epidermis and dermis takes place.

It has been speculated that, as in the case of amphibian limb and tail regeneration, a neurotrophic factor may be produced from the nervous tissue or the ependyma, or a signaling molecule/s from the wound epithelium may stimulate the regeneration and growth of the surrounding tissues (SIMPSON, 1970; ALIBARDI & MIOLO, 1990). In amphibians, among possible neurotrophic molecules, Fibroblast Growth Factors (FGFs, acidic or FGF1, and basic or FGF2) are the proteins that better mimic the action of trophic factor for regeneration of the limb (reviewed in GERAUDIE & FERRETTI, 1998). FGFs and their receptors are particularly localized in the wound epithelium (especially in the apical epidermal cup, AEC) and in the mesenchymal cells of the blastema in the newt or in the axolotl limbs (POULIN & CHIU, 1995; HAN et al., 2001; GIANPAOLI et al., 2003).

Recent immunocytochemical studies have shown that the regenerating spinal cord and nerves of lizards also contain relatively high levels of FGF1 and FGF2 (ALIBARDI & LOVIKU, 2009). This observation has extended the importance of FGFs as stimulator molecules for regeneration in reptiles, whose ancestors included the first amniotes that evolved during land adaptation. Therefore the process of regeneration in lizards represents an interesting model, closer to mammals than the amphibian model of regeneration, to analyze the factors limiting tissue regeneration in amniotes, including mammals (ALIBARDI, 2010b). Since regeneration in lizards is inhibited by wounding or cauterizing the regenerating tail, which then turns into a cicatrizing outgrowth, the study of the scarring process can reveal some differences in the expression of specific molecules, including growth factors. The cicatrization of the tail leads to the formation of a dense and irregular connective tissue, which replaces the normal

mesenchymal connective tissue of the blastema. It is not known whether a detectable amount of FGFs is also present in the limb of lizards, and in which tissue/s the factor is expressed in higher levels. In particular, the details of FGF immunolocalization in the wound epidermis and in the mesenchyme of the blastema are not known in lizards, and in reptilian tissues in general.

Using immunofluorescence and ultrastructural immuno-gold cytochemistry, the present study compares the localization of FGFs, in the tail wound epidermis and blastema mesenchyme with FGF localization in the limb wound in order to detect a possible difference in the presence of these growth factors that can be correlated with regeneration (tail) and scarring (limb).

## MATERIALS AND METHODS

The present study was conducted on a total of 61 adult lizards (*Podarcis sicula*) of both sexes, as detailed below. The animals were kept in a terrarium at 25-33°C with a photoperiod of 12-14 hours of light. The experimental procedures were in accordance with approved ethical protocols from the University of Bologna. The animals were kept a 4°C for 4-5 hours before amputation, following anesthesia using ethylic ether. Amputation was performed with a sharp razor blade at the 1/3 proximal of the rear limb, basically amputating most of the thigh or arm (about 1 mm or less was left as stump). At the same time also the tail was amputated at about 1/3 proximal, by twisting the tail to exploit the natural fracture planes present in the tail (autonomous planes). The animals were left at room temperature (22-27 °C) in cages over blotting paper for at least two days, with water available, to allow the stump surface to form a dry clot.

After two days the animals were returned to their previous cages at 25-33°C. The stump of the amputated tail or limb was collected at 2 days (n=4), 4 days (n=3), 6-7 days (n=4), 8-10 days (n=4), 12-14 days (n=3), 16-18 days (n=3),

22 days (n=3), and around 30 days (n=3). Other cicatrix outgrowths or short cones from the limbs (0.5-1 mm in length) were collected at 16 days (n=3), 22 days (n=4) and 35 days (n=5) after amputation. While the tail was regenerating by 8-18 days (2-10 mm), the limb appeared as a pale cicatrix at 22 and 35 days post-trauma.

Other lizards (n=12), after tail amputation and formation of the blastema, underwent the removal of 2-3 mm of the apical part of the blastema, which lead in some cases to the inhibition of regeneration. This occurred by the formation of a short cicatrix stump that rapidly formed a scaled outgrowth in the 3 weeks following post-removal. From some lizards (n=10), the fibrous scar outgrowths (at about 16 days in two individuals, at 3 weeks in five individuals, and 5 weeks post-trauma in three individuals) were then collected and immediately fixed.

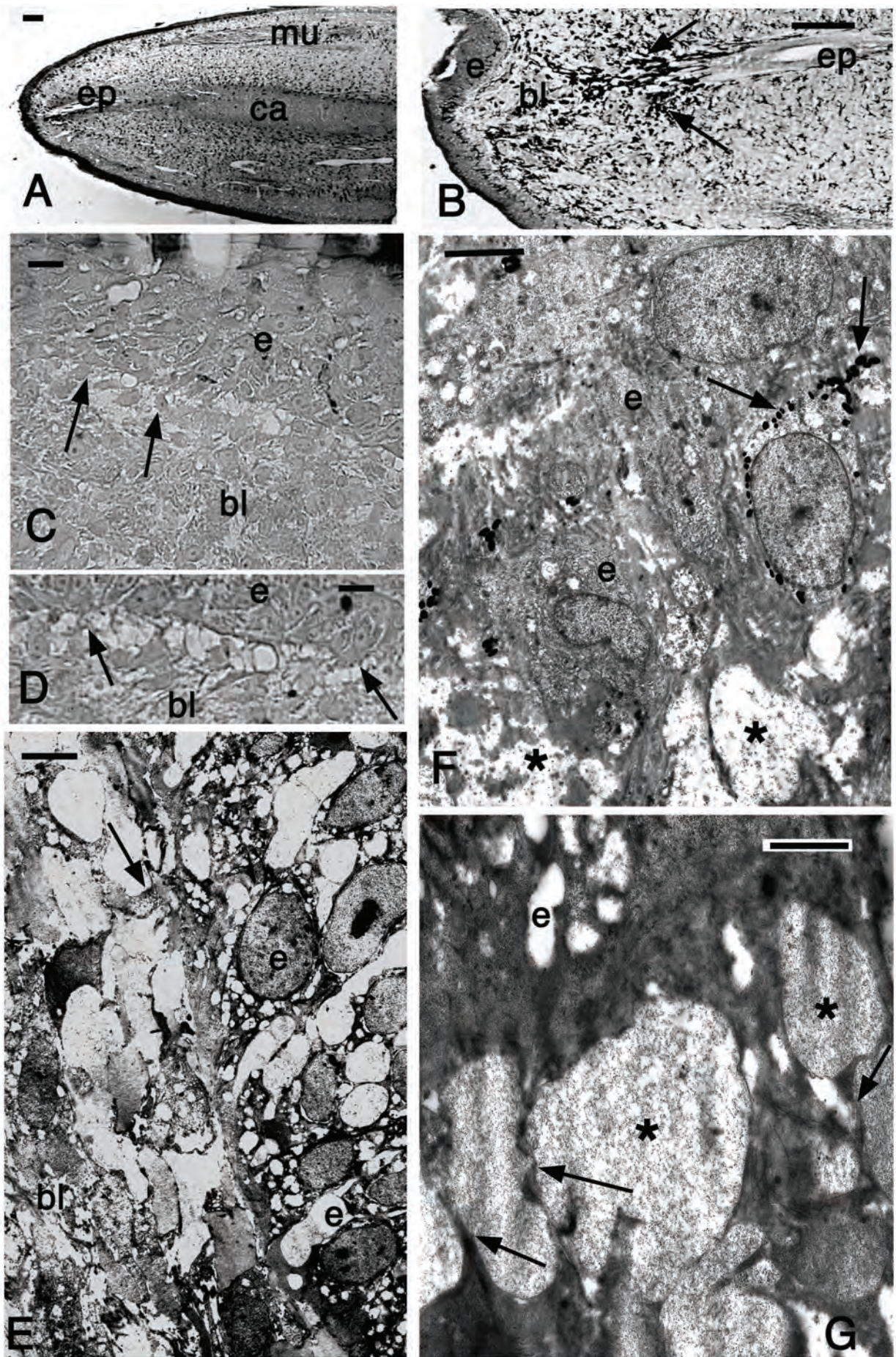
The normal blastema or regenerating cones and scarring outgrowths were halved with sharp scissors, and half of the organ was fixed with glutaraldehyde for morphological study, and the other half was fixed with Carnoy's fluid or paraformaldehyde for immunocytochemical study. Tissues were immediately fixed at 0-4°C in 2.5% glutaraldehyde in 0.12 M Phosphate buffer at pH 7.2 for 6-8 hours. These tissues were rinsed in the buffer, osmicated for two hours (2% OsO<sub>4</sub>), dehydrated and embedded in the hydrophobic Durcupan Resin according to standard protocols. The other tissues were fixed at 0-4°C in freshly-made 4% paraformaldehyde in 0.1 M Phosphate buffer at pH 7.4 for 7-8 hours, rinsed in buffer, dehydrated in ethanol and embedded in the hydrophilic Bioacryl resin (SCALA et al., 1992). Finally, other tissues were fixed in Carnoy's fluid for 4-5 hours at 0-4°C, dehydrated in ethanol, and embedded in Bioacryl resin.

The embedded tissues were sectioned longitudinally using an ultramicrotome, and semithin sections (2-3 mm thick) and thin sections (70-90 nm thick) were collected. Semithin sections were stained in 1% toluidine

blue for histological or immunohistochemical study (see details in Alibardi & Toni, 2005). Briefly, light microscopic immunocytochemistry was performed incubating the sections overnight at 0-4°C in the Fibroblast Growth Factor (FGF) antibodies diluted 1:200 in buffer (Tris 0.05 M at pH 7.6 containing 1% BSA). The FGF2 antibody (Sigma, F3393) was raised in rabbit against the 1-24 N-amino acid sequence of bovine bFGF. The anti FGF1 antibody was produced in rabbit injecting the entire sequence of the recombinant FGF1 (Sigma) (SCHULTZ et al., 1993). In control sections, the primary antibody was omitted. After being rinsed in buffer, the sections were incubated for 60 min at room temperature in a fluorescein-conjugated anti-rabbit antibody (Alexa 1:1000, or Sigma 1:100), rinsed in buffer, mounted in 10% glycerol, and observed under a fluorescence microscope equipped with a fluoroscein filter. Photographs were taken with a digital camera and computerised using Adobe Photoshop 5.0.

Thin sections of 30-80 nm thickness were collected on copper grids (those fixed in glutaraldehyde) or on nickel grids (those fixed in 4% paraformaldehyde). The sections on copper grids were routinely stained with uranyl acetate and lead citrate, rinsed, dried, and observed under CM-100 Philips and Hitachi-600 transmission electron microscopes.

The sections on nickel grids underwent immunogold labeling for FGF1 and FGF2 (as indicated above). Briefly, sections were incubated for 10 min in the Tris buffer containing 1% cold water fish gelatin to block non-specific binding sites, then the grids were incubated overnight at 0-4°C in the primary antibodies (FGF1 and FGF2 as above). Grids were again rinsed in the buffer, a 10 nm gold conjugated anti-rabbit secondary antibody was applied for one hour at room temperature, grids were rinsed in buffer and then in distilled water. Grids were stained for 6 min in 2% aqueous uranyl acetate, rinsed and observed with a CM-Philips 100 electron microscope operating at 80 kV.



## RESULTS

### Light microscopy and ultrastructure

The regenerating blastema of the conical new tail at 8-18 days of regeneration was surrounded by a multi-stratified (wound) epithelium, which produced a thin corneous layer (Fig. 1A, B). Close to the apical wound epithelium at the apex of the tail was located the ependymal ampulla, the foremost part of the central canal of the regenerating spinal cord, surrounded by a few growing axons and, more externally, by pigmented cells or melanophores (Fig. 1B).

Close analysis of the wound epidermis in the apical regions of the regenerative blastema at 7-16 days post-amputation showed that the boundary between epidermis and mesenchyme was often ill-defined (Fig. 1C, D). This histological aspect of the regenerating skin appeared clearly not just in tangentially-cut sections of the epidermal-dermal boundary but also in more central sections (perpendicularly-sectioned). It appeared that some keratinocytes were in continuity with mesenchymal cells without the presence of a basement membrane separating the epithelium from the mesenchyme.

Ultrastructural observations in these areas at 7-14 days post-injury showed the presence of numerous pale spaces or vesicles within the wound epithelium and between the epithelium

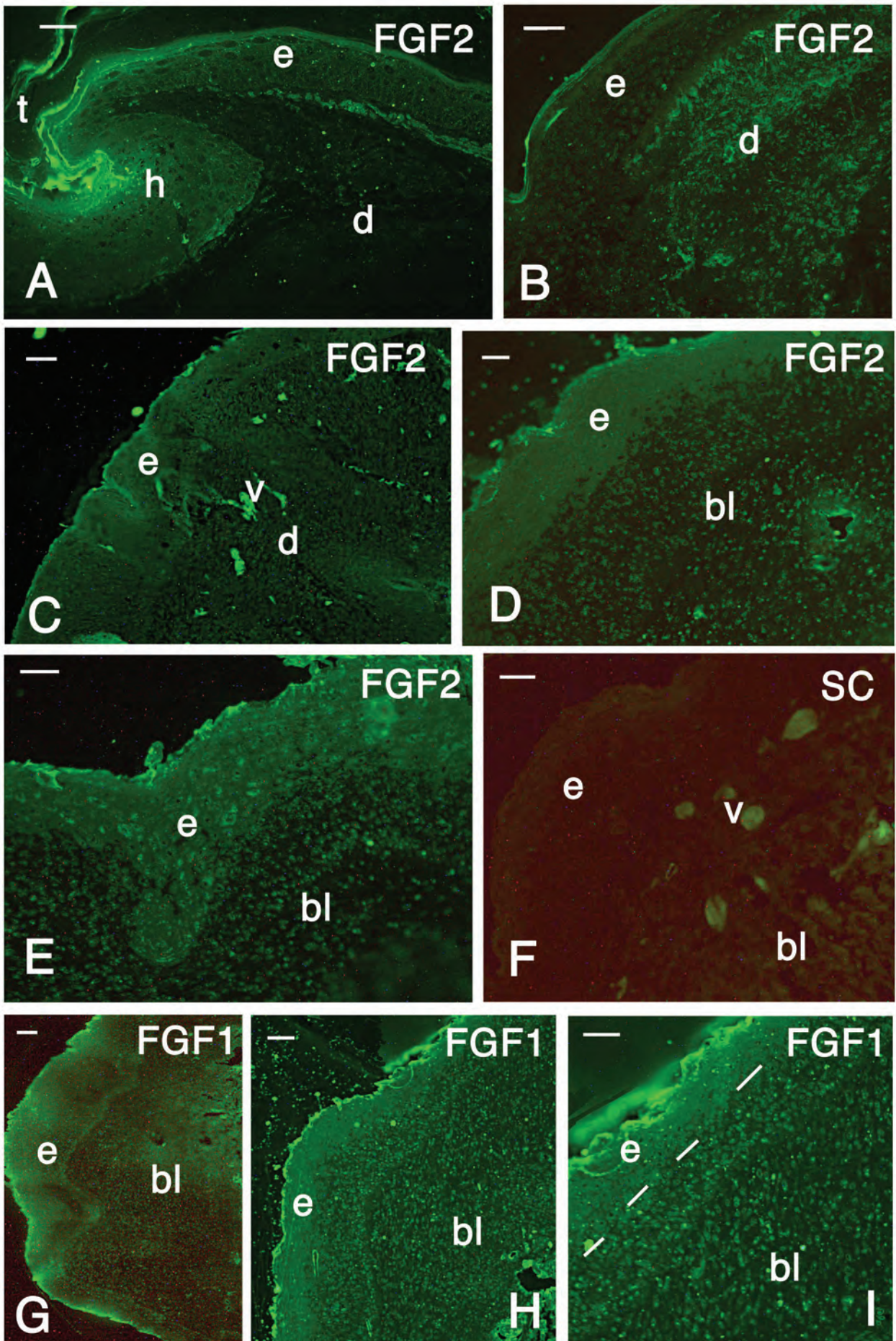
and the mesenchyme, while sparse cytoplasmic bridges disrupted the continuity of the epithelium (Fig. 1E). Detailed analysis of the pale spaces located among the basal keratinocyte elongation and mesenchymal cells of the blastema suggested that these structures were not extracellular or degenerating spaces among cells (Fig. 1F). Instead, at least in some cases, the pale spaces represented true sections of cytoplasmic blebs (stout elongations of the cytoplasm) from either epithelial or mesenchymal cells, and contained mainly free ribosomes and some flocculent, amorphous material (Fig. 1G). The cytoplasmic blebs were surrounded by a membrane or were enveloped by the cytoplasm of keratinocytes or mesenchymal cells present in these ill-defined, transitional zones (Fig. 1G).

### Light immunocytochemistry

The immunofluorescence for FGF2 (bFGF) showed that the reactive epidermis of the wounded scales close to the blastema was evenly stained at 6-14 days post-amputation (Fig. 2A). In comparison, FGF2 immunofluorescence was absent or limited to the basal layer in the epidermis of normal, unwounded scales, where the (reactive) dermis was also immunofluorescent (Fig. 2B).

The stratified wound epidermis of the tail at 7-18 days post-amputation also showed a diffuse immunofluorescence in keratinocytes, a positive

Fig. 1. – Light microscopic (A-D) and electron microscopic (E-G) aspects of the regenerating tail blastema. **A.** coniform regenerating tail at 12-14 days outlined by the thick wound epithelium and containing an apical ependyma ampulla surrounded by the blastematic mesenchyme. Bar: 50 mm. **B.** detail of the apical part of the regenerating tail showing numerous melanocytes (arrows) surrounding the ependymal ampulla and among blastema cells. Bar: 50 mm. **C.** detail of the apical wound epithelium at 7-8 days post-amputation. Some cells in the mesenchyme (arrows) seem in continuity with the epidermis. Bar: 10 mm. **D.** further detail of the wound epithelium at 7-8 days post-amputation showing two elongations (arrows) from epithelial cells into the underlying mesenchyme. Bar: 10 mm. **E.** Electron micrograph showing the interface between the wound epidermis and blastema cells at 7-8 days post-amputation. An epithelial elongation contacting the mesenchyme is seen (arrow). The asterisks indicate numerous pale spaces in the mesenchyme beneath the epithelium, representing sections of cytoplasmic blebs derived from the epithelium. Bar: 2 mm. **F.** detail of the most basal cells of the wound epithelium, which are not separated by a basement membrane from the underlying mesenchyme (arrows indicate pale or degenerating spaces between keratinocytes and mesenchymal cells). Bar: 2.5 mm. **G.** further detail of cytoplasmic blebs (asterisks) surrounded by keratinocyte bridges (double arrows). Bar 1 μm. **Abbreviations:** bl, blastema; c, regenerating cartilaginous axis (tubule); e, wound/regenerating epidermis; ep, ependymal ampulla; mu, regenerating muscles bundles.



fluorescence in the regenerating ependymal ampulla, but a lower immunoreactivity was instead present in mesenchymal cells of the blastema (Fig. 2C, D). FGF2-immunofluorescent keratinocytes were also seen in the forming epidermal pegs of regenerating scales (Fig. 2E). The controls showed no labeling in keratinocytes and a non-specific fluorescence was often observed in blood cells located within the vessels of the regenerating blastema (Fig. 2F).

The immunofluorescence for FGF1 (aFGF) showed a similar general localization to that of FGF2, but slightly more intense with the employed concentration of the antibodies in the wound epidermis, and it also showed similar localization in the mesenchymal cells and their nuclei in the regenerative blastema (Fig. 2G-I).

Detailed examination of different sections containing the apical wound epidermis stained for FGF2, of the regenerating tail at 7-14 days of regeneration (Fig. 3A, B), and of the limb at 7-8 and 12-14 days of regeneration (Fig. 3C-F), showed that the basal layers were not clearly distinct from the underlying mesenchyme. Therefore while some FGF-positive cells appeared confined within the epithelium (keratinocytes), other FGF2-positive cells were also present in the “frying” boundary between the epithelium and the mesenchyme. While the wound epidermis of the tail in the apical region maintained immunofluorescence for FGF2 at 18 days (elongating tail, see Fig. 3C) and longer, the immunofluorescence disappeared in the wound epithelium and connective tissue of the limb at 16, 22, and 35 days post-amputation (Fig. 3G, H).

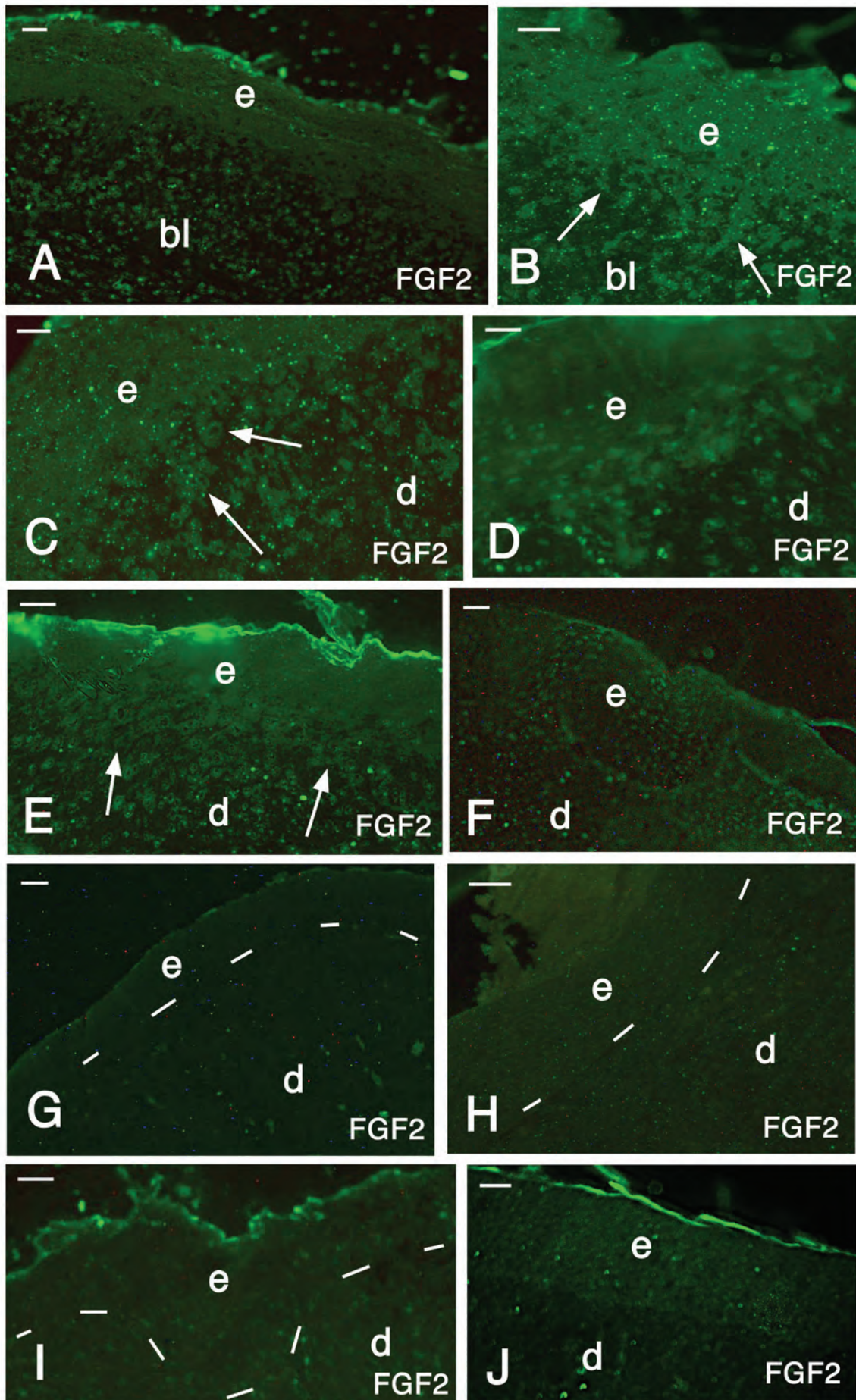
A similar lowering or a complete disappearance of the immunofluorescence, for FGF2 was noted in the epidermis of scarring tails at 16, 21, and 35 days post-injury (Fig. 3I, J). Controls sections were immunonegative (data not shown).

Detailed examination of sections that were immunoreacted for FGF1 (aFGF) showed a low to absent immunoreactivity in the normal epidermis and dermis (tail or limb) (data not shown). Immunofluorescence was instead observed in the wound epithelium of the tail and of the limb at 6-7 days post-amputation (Fig. 4A). At 12-14 and 25 days post-amputation the immunoreactivity for FGF1 disappeared in the limb while the epidermis became thinner and formed a thicker stratum corneum (Fig. 4B, C). A similar disappearance of FGF1 immunoreactivity was also noted in the epidermis and dermis of the scarring tail at 3 weeks post-amputation (fig. 4D). In mature scars of both limbs (35 days post-amputation) and tail (35 days post-amputation), the immunoreactivity for FGF1 in the epidermis was completely absent while the dense scar connective tissue appeared variably immunopositive for FGF1 (Fig. 4E, F). The controls from sections of tail and limb showed no immunoreactivity (Fig. 4G, H).

#### Ultrastructural immunocytochemistry in the tail blastema

The fine distribution of FGF2 in the apical wound epithelium showed that gold particles were diffusely distributed in the cytoplasm of all layers of the epidermis and among keratin bundles (Fig. 5A). We observed that nuclei

Fig. 2. – Immunofluorescence for FGF2 (A-E), control (F), and for FGF1 (G-I) in regenerating tail blastemas (12-14 days post-amputation). **A.** reactive scale proximal to the regenerating tail. Bar: 25 mm. **B.** normal scale lacking FGF2-immunoreactivity in the epidermis and immunolabeling in the dermis. Bar: 10 mm. **C.** apical blastema showing immunolabeling in the wound epidermis and little in the mesenchyme. Bar: 20 mm. **D.** immunolabeled wound epithelium and cells of the blastema. Bar: 20 mm. **E.** detail on epidermal bleb with immunofluorescent keratinocytes. Bar: 20 mm. **F.** immunonegative control where red blood cells inside blood vessels show a non-specific fluorescence. Bar: 20 mm. **G.** general view of blastema immunolabeled for FGF1. Bar: 20 mm. **H.** detail showing immunofluorescence in the wound epithelium and diffuse in the mesenchymal cells of the blastema. Bar: 20 mm. **I.** other detail of FGF1-labeling that also shows labeling in numerous nuclei of mesenchymal cells beneath the wound epidermis (dashes). Bar: 20 mm. **Abbreviations:** bl, mesenchymal blastema; d, dermis; e, epidermis; SC, serum control; v, blood vessel.





appeared less labeled, but quantification was not done. A higher concentration of gold particles was frequently observed along the wounding and incomplete plasma membrane contacting the mesenchyme (Fig. 5B). The labeling was mainly associated with the lamina lucida or with the lamina reticularis (non compacted parts of the basal lamina present beneath the lamina densa contacting the mesenchyme) but not specifically with the lamina densa (the dense component of the basement membrane). The latter was, however, discontinuous in the apical wound epidermis.

In control sections, both the cytoplasmic and basement membrane labeling was absent (Fig. 5C). FGF2 immunolabeling was also present in non-apical wound epithelium, although the labeling was even more diffuse in the cytoplasm and generally among keratin bundles of upper spinosus and pre-corneous keratinocytes (data not shown).

A lower, diffuse FGF2 immunolabeling was seen in the cytoplasm of mesenchymal cells of the blastema, including those apparently detaching from the epithelium (data not shown). A little labeling was often noted in the extracellular material associated with the plasma membrane (glycocalix) but little to no labeling was instead seen in the extracellular matrix of the blastema. Many endothelial cells of regenerating blood vessels in the blastema also contained a diffuse, cytoplasmic labeling (data not shown).

The immunogold labeling using the FGF1 antibody showed similar aspects to those observed with the FGF2 in the wound epithelium, but the nuclear labeling was often higher or similar to that present in the cytoplasm, in both epithelial and mesenchymal cells (data not shown). Also in mesenchymal cells the nuclear labeling often appeared prevalent over the cytoplasmic labeling, the latter was diffuse or more localized in the external cytoplasm of mesenchymal cells (Fig. 6A). The extracellular matrix of the cell surface (glycocalix) of blastema cells contained some gold particles that were virtually absent in the remaining extracellular matrix. The cytoplasm of endothelial cells of blood capillaries was also labeled for FGF1 (Fig. 6B). Control sections were immunonegative, as previously seen for keratinocytes of the wound epithelium.

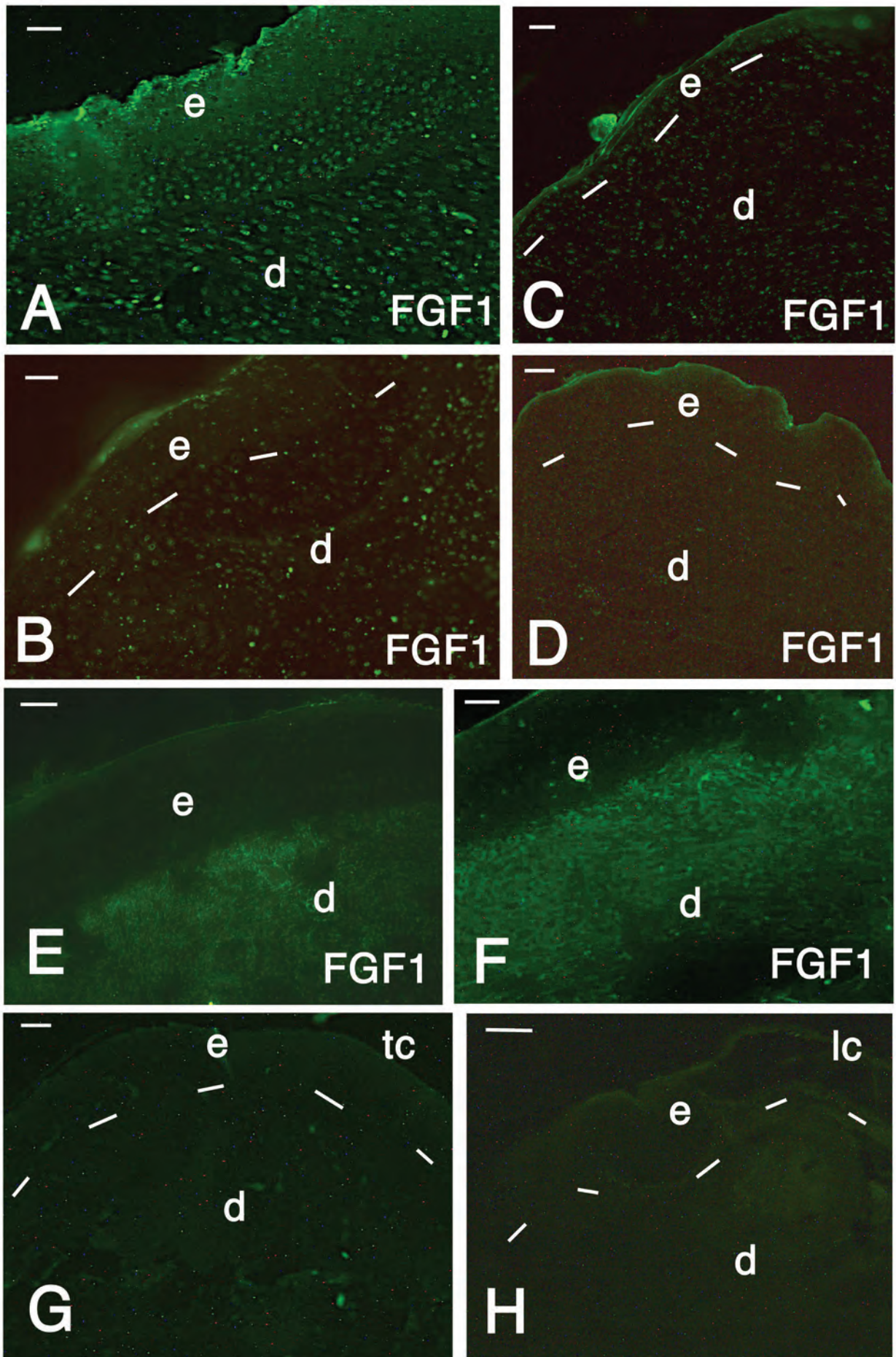
## DISCUSSION

### Localization of FGF in regenerating versus non-regenerating organs

The present, qualitative observations on the regenerative blastema of the tail and early limb (12-14 days post-trauma) of the lizard *P. sicula* confirm previous immunocytochemical studies on the lizard *Lampropholis guichenoti* (ALIBARDI & LOVIKU, 2009). The study has further indicated that FGF immunoreactivity is only present in the basal layers of the normal epidermis (where cell proliferation occurs),

---

Fig. 3. – Immunofluorescence for FGF2 in the epidermis and mesenchyme of tail (A-B), limb (C-H), and scarring tail (I-J). **A.** at seven days the immunopositive regenerating epidermis shows an uneven boundary with the mesenchyme. Bar: 230 mm. **B.** detail of the epithelium-mesenchyme boundary at 12 days post-injury where epithelial cells appear in continuity with the mesenchyme (arrows). Bar: 20 mm. **C.** the apical wound epithelium of a tail at 16-18 days also appears in continuity with mesenchymal cells. Bar: 20 mm. **D.** the thick epithelium of a limb at 7 days post-injury appears in continuity with the mesenchyme. Bar: 20 mm. **E.** at 12-14 days the immunopositive limb epithelium appears more regular and separated from the mesenchyme. Bar: 20 mm. **F.** other limb epithelium at 12-14 days where immunolabeling is reduced. Bar: 20 mm. **G.** almost immunonegative limb epidermis at 16-18 days post-amputation. Bar: 20 mm. **H.** immunonegative epidermis and mesenchyme at 22 days post-injury. Bar: 20 mm. **I.** almost immunonegative epidermis in injured regenerating tail at 16 days post-amputation. Bar: 20 mm. **J.** apical epidermis of cicatricial tail with reduced or absent immunoreactivity. Bar: 20 mm. **Abbreviations:** bl, blastema (mesenchyme); d, mesenchymal cells of the dermis; e, wound/regenerating epithelium. Dashes underline the epidermis.



and in the wound epidermis of the tail and, initially, also in the stump of the limb, where cell proliferation and migration are active (SIMPSON, 1961; COX, 1968; ALIBARDI, 1994a, b; ALIBARDI & TONI, 2005). The immunolocalization of FGFs in proliferating endothelial cells of the capillaries also suggests these growth factors are implicated in cell division (ALIBARDI, 1993). Normal differentiated tissues (dermis, muscles, bone or cartilage, normal nerves, fat tissue etc) do not show immunoreactivity for FGFs, indicating that the factors are absent and not active in mature tissues where little cell proliferation occurs.

These new data on a reptilian species are in line with previous information on the localization and mitogenic effect of FGFs on tissue regeneration in amphibians (BOILLY et al., 2000; POULIN et al., 1995; HAN et al., 2001; GIAMPAOLI et al., 2003). The present observations further suggest that the wound epidermis of the regenerating tail in the lizard also produces FGFs. Conversely, the lack of FGF immunolocalization after 2 and more weeks from the amputation seems somehow to be connected with scarring in the limb and in the wounded tail. It is not known whether the rapid formation of a basement lamina in the limb or in the scarring tail may be consequent to the loss of FGF in the epidermis. Such a loss may prevent epidermal-dermal communication or exchange of trophic or signaling factors, and regeneration and growth would be halted.

While FGF2 remains at least in the apical proliferating epidermis of the tail, both in the naturally scarring limb wound epithelium and in that of scarring tails, it finally disappears, an indication that cell proliferation rapidly terminates in these tissues. Moreover, the

epithelium forms a differentiated basement membrane and also a hard corneous layer like the corneous layer present in normal, mature scales. The potential to form an AEC containing FGF, which appears possible in the tail blastema, is therefore impeded in both the limb and in the scarring tail. In conclusion, the present study has shown that also in the lizard, an amniote with high regeneration ability in the tail, the higher levels of FGFs are present in regenerating tissues. Future studies should evaluate whether specific FGFs such as FGF8, FGF10, or FGF7, are present in regenerating vs non-regenerating lizard tissues.

#### Ultrastructural localization and epithelium-mesenchymal communication

The present ultrastructural study has also indicated that diffuse cytoplasmic and nuclear distributions of FGF1 and FGF2 are present in regenerating tissue, especially in keratinocytes of the wound epithelium more so than in blastema cells. FGF is also localized in endothelial cells of forming blood vessels. The study brings further evidence that an epithelial-mesenchymal transformation/transition (EMT) also occurs during tail and limb regeneration in lizards (ALIBARDI, 2010a,b). The EMT is a process that occurs during embryogenesis (epithelium into mesenchyme, see HAY, 1995), inflammatory reactions in various adult organs (KALLURI & NEILSON, 2003; IWANO et al., 2002), and in cancer (RADISKY, 2005; LEE et al., 2006; KLYMKOWSKY & SAVAGNER, 2009).

The immunolocalization at the ultrastructural level of FGFs in different cells of the lizard blastema has shown no specific organelle

---

Fig. 4. – Immunofluorescence for FGF1 in the limb (A-D), scarring tail (E-F), and in controls (G-H). **A.** regenerating skin with thick epidermis of a limb at 12 days post-amputation. Bar 20 mm. **B.** limb skin at 16-18 days with no immunofluorescence in either epidermis or dermis. Bar: 20 mm. **C.** immunonegative limb skin at 22 days post-amputation. Bar: 20 mm. **D.** limb scarred skin at 35 days post-amputation with reactive dense dermis. Bar: 20 mm. **E.** immunonegative tail scar skin in both epidermis and dermis (21 days post-amputation). Bar: 20 mm. **F.** other tail scar at 35 days post-amputation with immunofluorescent dermis. Bar 20 mm. **G.** serum control for the tail. Bar: 20 mm. **H.** serum control for the limb. Bar: 20 mm. **Abbreviations:** d, mesenchymal cells of the dermis; e, wound/regenerating epithelium; lc, serum control for the limb; tc, serum control for the tail.

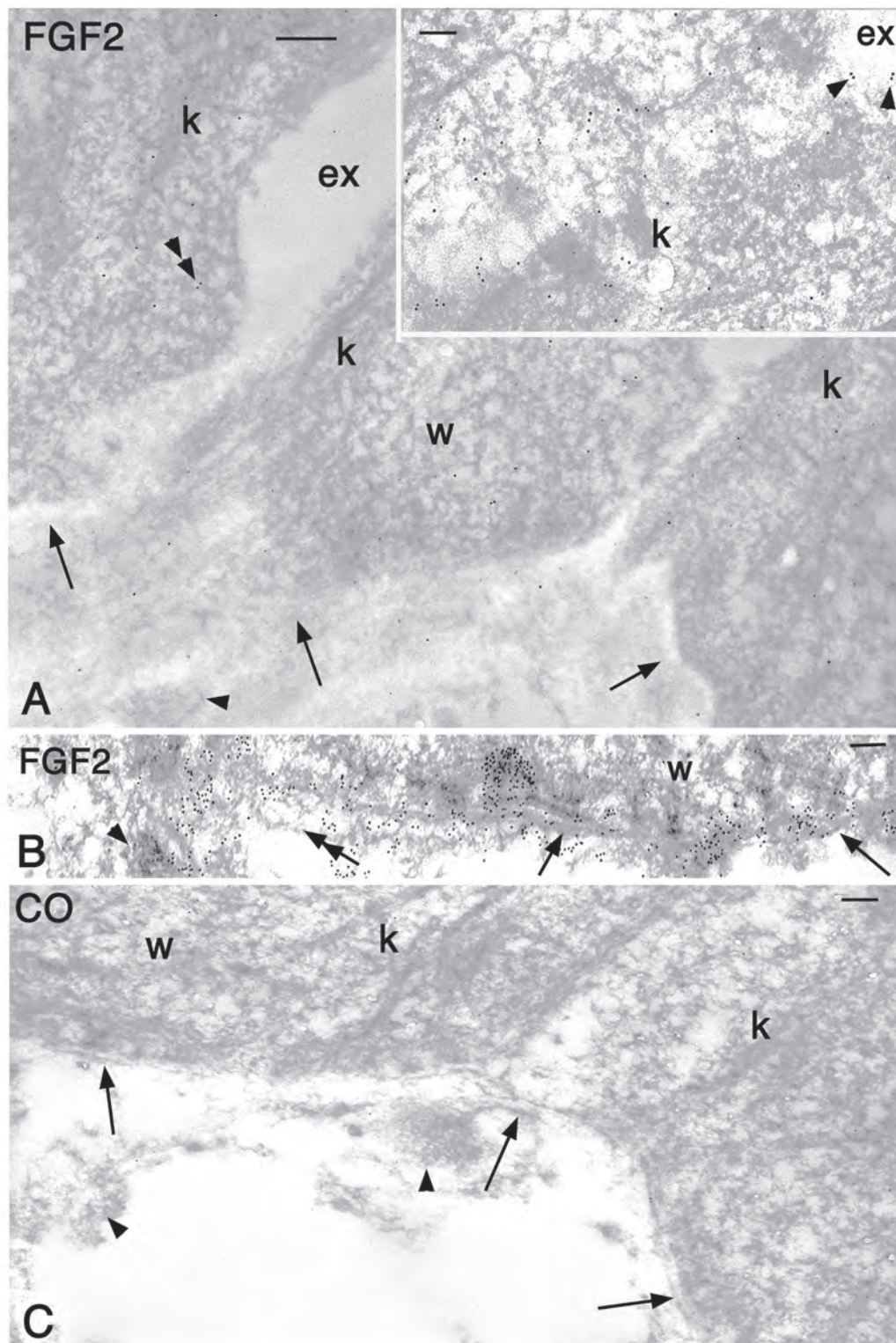


Fig. 5. – FGF2 immunogold-labeling of tail apical wound epithelium. **A.** detail of basal part of the wound epithelium with wavy basement membrane (arrows). The arrowhead indicates likely dermal cell process. The double arrowheads indicate the loose keratin network present in these cells. Bar: 200 nm. The inset (Bar: 100 nm) shows the diffuse labeling in the cytoplasm of a wound keratinocyte, and around vesicles (arrowheads). **B.** detail of intense labeling along the incomplete basement membrane (arrows) underlying apical wound keratinocytes. The arrowhead indicates some likely hemi-desmosomal material. Bar: 100 nm. **C.** immuno-negative control detail of the basal cytoplasm of wound epithelium cells with basement membrane (arrows). Arrowheads indicate amorphous extracellular material. The double arrow indicates the amorphous part of the basement membrane. Bar: 100 nm. **Abbreviations:** ex, extracellular space among keratinocytes; k, keratin bundle; w, wound epithelium.

distribution as this growth factor is synthesized and apparently released through a non conventional, ER- and Golgi-independent mechanism of cellular extrusion (NICKEL & SEEDORF, 2008). In the regenerating wound epithelium of lizard, keratinocytes probably produce an increased quantity of FGFs that may possibly relate to the EMT.

The passage of FGF through the basement membrane is strongly suggested by the present TEM observations. Our study indicates that FGF2 accumulates along the immature basement membrane of the wound epithelium, and it is most likely released by the wound keratinocytes. The observed immuno-localization suggests that the continuous production of FGFs from regenerating keratinocytes can locally stimulate blastema cells to proliferate, as has been previously indicated for the blastema of amphibians (BOILLY et al., 2000; POULIN et al., 1995; HAN et al., 2001; GIAMPAOLI et al., 2003). The extrusion of FGF through the plasma membrane following a diffusion mechanism driven by the extracellular capture of FGF2 by heparan sulphate has been indicated as a characteristic of the extracellular release of FGF2 (NICKEL & SEEDORF, 2008).

A free cytoplasmic localization of FGF2 has been reported for fibroblasts (AKTAS & KAYTOU, 2000) and developing neurons but not in glial cells (JANET et al., 1987). Another study however found that FGF2 was present in both the cytoplasm and nuclei of astrocytes and in a few types of adult neurons (WOODWARD et al., 1992). Other ultrastructural studies on FGF1 localization have indicated that this growth factor is also present within stimulated adult neurons but not extracellularly (ELDE et al., 1991). Only in mastocytes is bFGF prevalently associated with secretory granules, and therefore in these cells FGF2 follows the classic secretory pathway (QU et al., 1998).

In blastema cells of the lizard tail, the diffuse immunolocalization of FGFs in the cytoplasm and glycocalyx suggests that they may act in an autocrine manner on cell proliferation, as pos-

tulated for amphibian blastema. The nuclear localization of FGF1 has been reported also in previous work on fibroblasts (AKTAS & KAYTON, 2000), neurons (Janet et al., 1987; ELDE et al., 1991), and astrocytes (WOODWORTH et al., 1992). These results indicated that immunodetection of these molecules may vary in relation to the physiological or differentiative state of these cells.

In conclusion, the present morphological study indicates that a process of EMT is operating during early stages of tail and limb regeneration in lizards (an amniote model of regeneration, see ALIBARDI, 2010b), and that FGFs, especially FGF2, are involved in maintaining a growing front for tail regeneration, a process initially present but soon aborted in the scarring limb or tail. It is not known whether the observed FGF-immunoreactivity may also be due to more specific forms of FGFs (eg FGF8 or FGF10) or to a potential lizard KGF (FGF7), the typical growth factor for the epidermis and hairs in mammals (GUO et al., 1996; ANDREADIS et al., 2001).

## ACKNOWLEDGEMENTS

The study was mainly self-supported (Comparative Histolab) and in part by the University of Bologna (RFO 2007). Initially in the study, some of the FGF antibodies were kindly provided from Drs J. McAvoy and F. Loviku (University of Sydney).

## REFERENCES

- AKTAS G, & KAYTON R (2000). Ultrastructural immunolocalization of basic fibroblast growth factor in fibroblasts and extracellular matrix. *Histochemistry and Cell Biology*, 113: 227-233.
- ALIBARDI L (1993). Observations on the ultrastructure of blood capillaries in the regenerating blastema of lizard in relation to the blood-brain barrier. *European Archives of Biology*, 104: 21-27.
- ALIBARDI L (1994a). Fine autoradiographical study on scale morphogenesis in the regenerating tail of lizards. *Histology and Histopathology*, 9: 119-134.

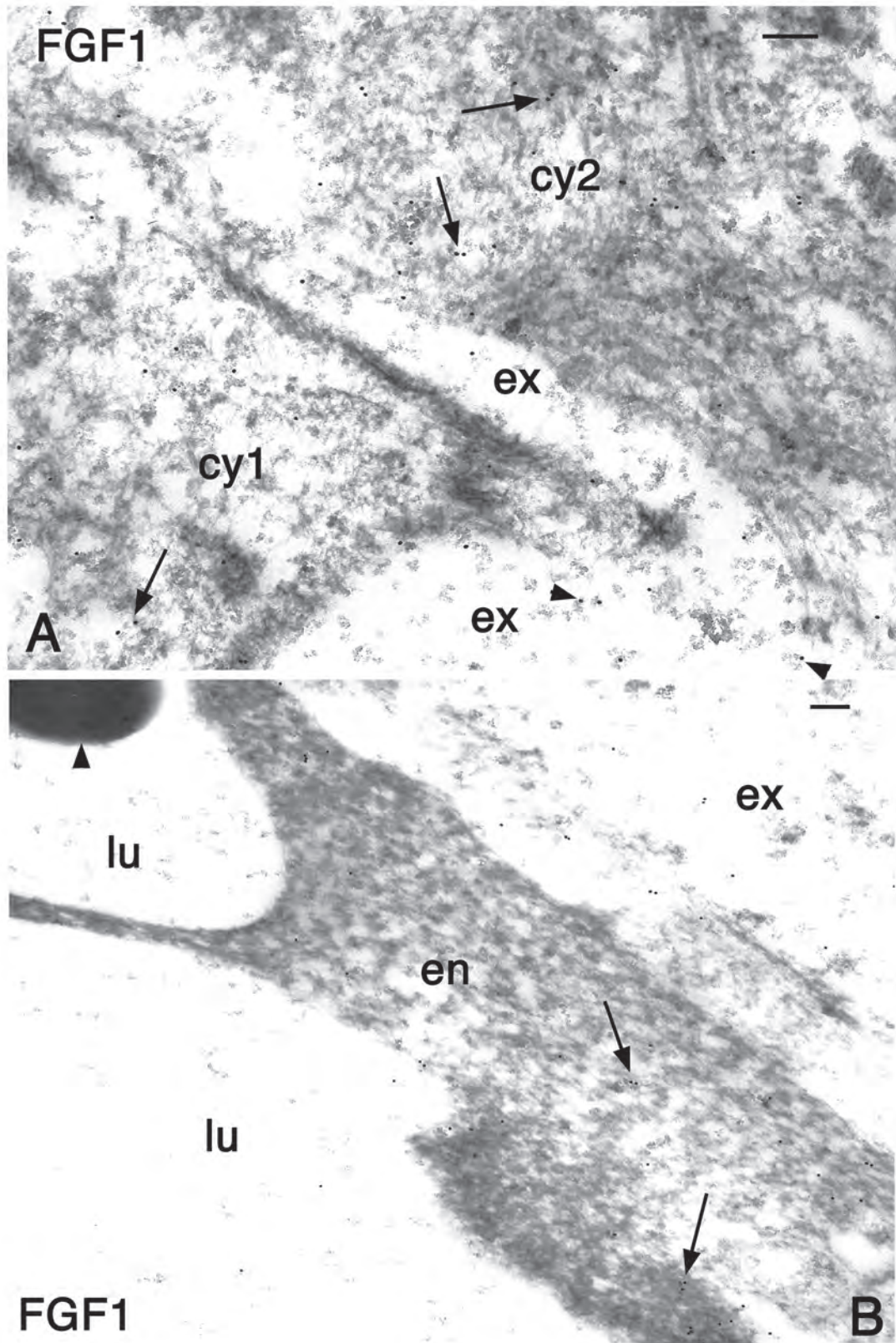


Fig. 6. – FGF1 immunogold-labeling of blastema (mesoderm, **A**) cells and endothelial cell (**B**). **A**. diffuse FGF1 immunolabeling (arrows) in two blastema cells with few gold particles present in the extracellular space close to the surface (arrowheads). Bar: 100 nm. **B**. endothelial cell with diffuse immunolabeling (arrows). The arrowhead indicates a red blood cell. Bar: 100 nm. **Abbreviations**: cy1 and cy2, cytoplasm of cell one and two; en, endothelial wall; ex, extracellular space; lu, lumen of the capillary.

- ALIBARDI L (1994b). Modifications of the dermis during scale regeneration in the lizard tail. *Histology and Histopathology*, 9: 733-745.
- ALIBARDI L (2010a). Ultrastructural features of the process of wound healing after tail and limb amputation in lizard. *Acta Zoologica*, 91: 306-318.
- ALIBARDI L (2010b). Morphological and cellular aspects of tail and limb regeneration in lizard. *Advances in Anatomy and Cell Biology*, 207: 1-129.
- ALIBARDI L & SALA M (1988). Fine structure of the blastema in the regenerating tail of the lizard *Podarcis sicula*. *Bollettino di Zoologia*, 55: 307-313.
- ALIBARDI L & SALA M (1989). Ependymal fine structure and secretory activity during early phases of tail regeneration in lizard. *Archivio Italiano di Anatomia e Embriologia*, 94: 55-69.
- ALIBARDI L & MIOLO V (1990). Fine observations on nerves colonizing the regenerating tail of the lizard *Podarcis sicula*. *Histology and Histopathology*, 5: 387-396.
- ALIBARDI L & TONI M (2005). Wound keratins in the regenerating epidermis of lizard suggest that the wound reaction is similar in the tail and limb. *Journal of Experimental Zoology*, 303A: 845-860.
- ANFREADIS ST, HAMOEN KE, YARMUSH ML, & MORGAN JR (2001). Keratinocyte growth factor induces hyperproliferation and delays differentiation in a skin equivalent model system. *FASEB J*, 15: 898-906.
- BARBER LW (1944). Correlation between wound healing and regeneration in forelimbs and tails of lizards. *Anatomical Record*, 89: 441-453.
- BELLAIRS A D'A, & BRYANT SV (1985). Autotomy and regeneration in reptiles. *In: GANS C, BILLET F, MADERSON PFA (eds), Biology of the Reptilia vol 15B*. John Wiley and Sons, New York, pp. 302-410.
- BOILLY B, VERCOUTTER-EDOUART AS, HONDERMARCK H, NURCOMBE V, & LE BOUHIS X (2000). FGF signals for cell proliferation and migration through different pathways. *Cytokine and Growth Factors Review*, 11: 295-302.
- CARLSON BM (2007). *Principles of regenerative biology*. Academic Press-Elsevier, USA.
- COX PG (1969). Some aspects of tail regeneration in the lizard *Anolis carolinensis*. I. A description based on histology and autoradiography. *Journal of Experimental Zoology*, 171: 127-150.
- ELDE R, CAO Y, CINTRA A, CLARK BRELJE T, PELTO-HUIKKO M, JUNTILLA T, FUXE K, PETTERSON RF, & HOKFELT T (1991). Prominent expression of acidic fibroblast growth factor in motor and sensory neurons. *Neuron*, 7: 349-364.
- GERAUDIE J, & FERRETTI P (1998). Gene expression during amphibian limb regeneration. *International Review of Cytology*, 180: 1-50.
- GIANPAOLI S, BUCCI S, RAGGHIANI R, MANCINO G, ZHANG F, & FERRETTI P (2003). Expression of FGF2 in the limb blastema of two Salamandridae correlates with their regenerative capability. *Proceedings of Biological Sciences*, 270: 2197-2205.
- GUO L, DEGENSTEIN L, & FUCHS E (1996). Keratinocyte growth factor is required for hair development but not for wound healing. *Genes and Development*, 10: 165-175.
- HAN MJ, AN JY, & KIM WS (2001). Expression pattern of FGF-8 during development and limb regeneration of the axolotl. *Developmental Dynamics*, 220: 40-48.
- HARTY M, NEFF AW, KING MW, & MESHER AL (2003). Regeneration or scarring: an immunologic perspective. *Developmental Dynamics*, 226: 268-279.
- HAY ED (1996). An overview of epithelio-mesenchymal transformation. *Acta Anatomica*, 154: 8-20.
- HUGHES A, NEW D (1959). Tail regeneration in the geckonid lizard, *Sphaerodactylus*. *Journal of Embryology and experimental Morphology*, 7: 281-302.
- IWANO M, PLIETH D, DANOFF TM, XUE C, OKADA H, & NEILSON EG (2002). Evidence that fibroblasts derive from epithelium during tissue fibrosis. *Journal of Clinical Investigations*, 110: 341-350.
- JANET T, MICHE M, PETTMAN B, LABOURDETTE G, & SENSENBRENNER M (1987). Ultrastructural localization of fibroblast growth factor in neurons of rat brain. *Neuroscience Letters*, 80: 153-157.
- KALLURI R, & NEILSON EG (2003). Epithelial-mesenchymal transition and its implications for fibrosis. *Journal of Clinical Investigations*, 112: 1776-1784.
- KLYMKOWSKY MW, & SAVAGNER P (2009). Epithelial-mesenchymal transition. A cancer researcher's conceptual friend and foe. *American Journal of Pathology*, 174: 1588-1593.
- LEE JM, DEDHAR S, KALLURI R, & THOMPSON EW (2006). The epithelial-mesenchymal transition: new insights in signalling, development, and disease. *Journal of Cell Biology*, 172: 973-981.
- MARCUCCI E. (1925). La rigenerazione degli arti nei

- rettili. Bolletino Società dei Naturalisti di Napoli, 38: 8-17.
- MARCUCCI E (1930) Il potere rigenerativo degli arti nei rettili. Archivio Zoologico Italiano, 14: 227-252.
- MESHER AL (1996). The cellular basis of limb regeneration in urodeles. International Journal of Developmental Biology, 40: 785-795
- NICKEL W, & SEEDORF M (2008). Unconventional mechanisms of protein transport to the cell surface of eukariotic cells. Annals Reviews of Cell Developmental Biology, 24: 287-308.
- POULIN ML, & CHIU IM (1995) Re-programming of expression of the KGFR and bek variants of fibroblast growth factor receptor 2 during limb regeneration in newts (*Notophthalmus viridescens*). Developmental Dynamics, 202: 378-387.
- QU Z, KAYTON RJ, AHMADI P, LIEBLER JM, POWERS MR, PLANCK SR, & ROSENBAUM JT (1998). Ultrastructural immunolocalization of basic growth factor in mast cell secretory granules: morphological evidence for bFGF release through degranulation. Journal of Histochemistry and Cytochemistry, 46: 1119-1128.
- RADISKY DC (2005). Epithelial-mesenchymal transition. Journal of Cell Sciences, 118: 4325-4326.
- SIMPSON S. B. Jr. 1965. Regeneration of the lizard tail. In: KIORTIS V & TRAMPBUSH HAL (eds), Regeneration in animals and related problems. North-Holland, Amsterdam, pp. 431-443.
- SIMPSON SB Jr (1970). Studies on regeneration of lizards' tail. American Zoologist, 10: 157-165.
- STOCUM D (2006). Regenerative biology and medicine. Academic Press, San Diego, USA.
- SCHULTZ MW, CHAMBERLAIN CG, DE JONGH RU, & MCAVOY JW (1993). Acidic and basic FGF in ocular media and lens: implications for lens polarity and growth patterns. Development, 118: 117-126.
- WHIMSTER I.W. (1978). Nerve supply as a stimulator of the growth of tissues including skin. II. Animal evidence. Clinical Experimental Dermatology, 3: 389-410.
- WOODWARD WR, NISHI R, MESHUL CK, WILLIAMS TE, COULOMBE M, & ECKENSTEIN FP (1992). Nuclear and cytoplasmic localization of basic fibroblast growth factor in astrocytes and CA2 hippocampal neurons. Journal of Neuroscience, 12: 142-152.
- ZIKA JM (1969). A histological study of the regenerative response in a lizard, *Anolis carolinensis*. Journal of Experimental Zoology, 172: 1-8.

*Received: June 4th, 2010*

*Accepted: November 7th, 2011*

*Branch editor: Schockaert Ernest*