

## Effects of 4-Nonylphenol on ACTH cells in *Podarcis siculus* lizard

Rossana FAVORITO, Gianluca CAMMISA,  
Maria C. GRIMALDI, Ida FERRANDINO

Dipartimento delle Scienze Biologiche, Università degli Studi di Napoli Federico II – Napoli,  
Italy; ida.ferrandino@unina.it

**Riassunto.** Il nonilfenolo (NP) è un prodotto chimico che fa parte di una serie di sostanze eterogenee definite Distruttori Endocrini (ED). Il suo ampio impiego industriale giustifica l'attuale interesse circa le possibili ripercussioni sulla salute dell'uomo. Diversi studi riportano l'azione simil-estrogenica del nonilfenolo sulle cellule gonadotrope; poco è invece riportato circa la sua azione sulle altre cellule adenoipofisarie. Pertanto nel presente lavoro riportiamo le osservazioni isto-morfologiche relative all'azione del nonilfenolo sulle cellule corticotrope (ACTH) dell'ipofisi in *Podarcis siculus*, importante bioindicatore. Lo studio è stato condotto su due gruppi di lucertole, uno sottoposto ad iniezioni quotidiane intraperitoneali protratte per 12 giorni di 4-para-nonilfenolo 1/100 della dose letale media (LD<sub>50</sub>) per i topi e l'altro di controllo. Attraverso colorazioni istologiche si è osservato che l'ipofisi degli animali trattati non subisce particolari alterazioni morfologiche. Le cellule ad ACTH, rivelate mediante la tecnica immunoistochimica ABC, invece aumentano in quantità e compaiono anche nella zona caudale dove sono normalmente assenti. L'azione tossica del nonilfenolo evidentemente non si limita, così come ad oggi riportato in letteratura, alle sole cellule gonadotrope ma si estende anche sulle cellule ad ACTH, su cui è utile pertanto condurre ulteriori studi.

**Keywords.** Nonylphenol, lizard, ACTH cells, pituitary gland.

Endocrine disruptors (ED<sub>s</sub>) are both naturally and synthetic chemicals that interfere with the endocrine system and consequently cause health effects in humans and animals (Bonefeld-Jergensen *et al.*, 2007). They are chemicals generally similar in structure to oestrogens or androgens and interfere with the action of endogenous steroid hormones. ED<sub>s</sub> include drugs, like diethylstilbesterol (DES), pesticides, like dichlorodiphenyltrichloroethane (DDT), and industrial chemicals, as nonylphenol (NP) (Choi and Jeung, 2003). NP is widely used as non-ionic surfactant in many detergent formulations for domestic and industrial use. It

has been found in polyvinyl chloride, which is used in the food processing and packaging industries and this is a potential exposure to NP by the consumption of contaminated foods and drinking water (Guenther *et al.*, 2002). For all these reasons, in recent years there have been much studies on the action of NP on human and other mammals. The great bulk of these researches has been to study the oestrogenic or anti-androgenic properties of this chemical with its capacity to influence vital endocrine functions in human and wildlife (Chitra *et al.*, 2002; Yadetie and Male, 2002; Masutomi *et al.*, 2004; Aydogan *et al.*, 2008). More recently there has been paid attention on the effects of NP, or ED<sub>5</sub>, on the other endocrine systems as the adrenal function (Hinson, 2006). For this reason we have analyzed the effect of NP on the ACTH cells in *Podarcis siculus* lizard. The study was performed on twenty adult lizards of *P. siculus*, captured in captivity near Naples (Italy) in the period of May-June and kept under controlled conditions of light and temperature. The same ones have been divided in two groups, one of which, of ten specimens, was submitted to treatment by daily intraperitoneal injections of 4-NP (Fluka, Germany) at median lethal dose (LD<sub>50</sub>) of 0.172 µg/g of body weight (see Kimura *et al.*, 2006).

Ground nut oil was used as the vehicle for NP. Control lizards were indeed treated only with ground nut oil. Treated and control animals were killed 12 days later. Experiments were performed with the approval of institutional committees: all efforts were made to avoid animal suffering and to minimize the number of animals used. All animals were killed under anaesthesia by a cervical cut. The gland was studied in toto with the brain. Serial sections of 6 µm were processed for routine histological and immunohistochemical staining. For immunohistochemical staining sections were processed according to the ABC technique using the following heterologous antiserum: anti-synthetic ACTH<sup>1-24</sup> (Biogenesis, UK) at working dilutions of 1:100. Visualization was carried out using the Vectastain Elite ABC kit (Vector, USA). Antibody specificity was assessed by omitting the primary antisera and by absorbing each antiserum with the specific hormone. In all control lizards the pituitary gland appeared compact with greatly vascularized cellular cordons in all pars distalis (PD). In the rostral (RPD) and medial (MPD) pars distalis the cells were mostly basophilic or chromophobic (Fig. 1a), indeed in the caudal pars distalis (CPD) they were almost acidophilic. A lot of basophilic cells were also observed in the pars intermedia (PI) of the gland. In the treated animals after 12 injections of 4-NP the general morphology of the pituitary tissue appeared similar of that observed in the control lizards (Fig. 1b). By immunohistochemical detection, ACTH cells appeared like a distinct cellular population with a specific distribution in the PD and in the PI (Fig. 1c). In the PD they were normally present in the rostral and medial regions, but they were absent in the caudal area (Figs. 1c and 1e). They appeared organized under shape of sharp cellular cordons. A lot of ACTH cells were also revealed in the PI (Fig. 1d). ACTH cells were elongated in shape, with a central nucleus and abundant cytoplasm in the PD, as well as in the PI. In the treated animals after 12 injections, ACTH cells appeared increased in the occurrence and they were observed in the caudal region too (Figs. 1f and 1g) while they were absent in the control specimens. ACTH cells of treated lizards appeared with a very strong cytoplasmic immunoreactivity and with the alteration of their cordonal organization. In the caudal pars

distalis ACTH cells appeared small and round in shape. By this data we can conclude that NP exerts an evident dysregulation on ACTH cells in *P. siculus* lizard and so it is toxic for non gonadotropic cells also. Therefore we think it is important to continue the investigation about the hazard effects of NP on the endocrine system in toto and *P. siculus* lizard appears to be a good model for this investigation.

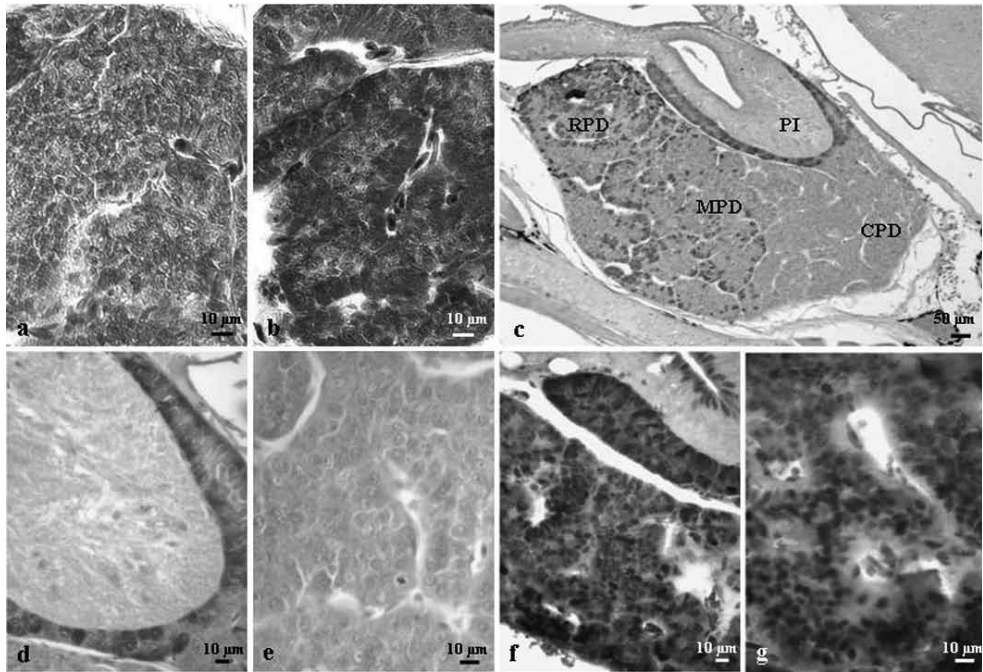


Fig. 1. Sagittal sections of *P. siculus* pituitary gland. (a) Mallory stain. Control lizard. Caudal pars distalis (CPD). (b) Mallory stain. Treated lizard. CPD. (c) ABC technique, ACTH cells (in brown). Control lizard, showing the occurrence of ACTH cells in the rostral (RPD), medial (MPD) pars distalis and pars intermedia (PI). (d) Detail of Fig. 1c: ACTH cells in PI. (e) Detail of Fig.1c of CPD: note the absence of ACTH cells. (f) MPD and PI of treated lizard. Note the increase in the occurrence of ACTH cells. (g) In CPD the ACTH cells of treated lizards appeared small and round in shape with a very strong cytoplasmic immunoreactivity.

## References

- Aydođan, M., Korkmaz, A., Barlas, N., Kolankaya, D. (2008): The effect of vitamin C on bisphenol A, nonylphenol and octylphenol induced brain damages of male rats. *Toxicology*. 249 (1): 35-39.
- Bonefeld-Jørgensen, E.C., Long, M., Hofmeister, M.V., Vinggaard, A. M. (2007): Endo-

- crine-disrupting potential of bisphenol A, bisphenol A dimethacrylate, 4-n-nonylphenol, and 4-n-octylphenol in vitro: new data and a brief review. *Environ. Health Perspectives* 115 (Suppl. 1): 69-76.
- Chitra, K.C., Latchoumycandane, C., Mathur, P.P. (2002): Effect of nonylphenol on the antioxidant system in epididymal sperm of rats. *Arch. Toxicol.* 76(9): 545-551.
- Choi, K.C., Jeung, E.B. (2003): The biomarkers and endocrine disruptors in mammals. *J. Kimura Repr. Dev.* 49 (5): 337-345.
- Guenther, K., Heinke, V., Thiele, B., Kleist, E., Prast, H., Raecker, T. (2002): Endocrine disrupting nonylphenols are ubiquitous in food. *Environ. Sci. Technol.* 36 (8): 1676-1680.
- Hinson, J.P. (2006): Effects of endocrine-disrupting chemicals on adrenal function. *Best Pract. Res. Clin. Endocrinol. Metab.* 20 (1): 111-120.
- Kimura, T., Suzuki, M., Totsukawa, K. (2006): Effect of gestational exposure to nonylphenol on the development and fertility of mouse offspring. *J. Reprod. Dev.* 52 (6): 789-795.
- Masutomi, N., Shibutani, M., Takagi, H., Uneyama, C., Lee, K.Y., Hirose, M. (2004): Alteration of pituitary hormone-immunoreactive cell populations in rat offspring after maternal dietary exposure to endocrine-active chemicals. *Arch. Toxicol.* 78 (4): 232-240.
- Yadete, F., Male, R. (2002): Effects of 4-nonylphenol on gene expression of pituitary hormones in juvenile Atlantic salmon (*Salmo salar*). *Aquat. Toxicol.* 58 (1-2): 113-129.